Journal of Invertebrate Pathology 106 (2011) 165–173

Contents lists available at ScienceDirect

Journal of Invertebrate Pathology

journal homepage: www.elsevier.com/locate/jip

Gross and microscopic morphology of lesions in Cnidaria from Palmyra Atoll, Central Pacific

Gareth J. Williams [a,1,2], Thierry M. Work [b,1], Greta S. Aeby [c], Ingrid S. Knapp [a], Simon K. Davy [a,*]

[a] School of Biological Sciences & Centre for Marine Environmental and Economic Research, Victoria University of Wellington, P.O. Box 600, Wellington, New Zealand
[b] US Geological Survey, National Wildlife Health Center, Honolulu Field Station, Honolulu, HI 96850, USA
[c] Hawaii Institute of Marine Biology, P.O. Box 1346, Kaneohe, HI 96744, USA

ARTICLE INFO

Article history:
Received 19 May 2010
Accepted 7 August 2010
Available online 13 August 2010

Keywords:
Coral disease
Coral lesion
Growth anomaly
Tissue loss
Discoloration
Hyperplasia
Necrosis
Fungi
Scleractinian coral
Soft coral
Zoanthid

ABSTRACT

We conducted gross and microscopic characterizations of lesions in Cnidaria from Palmyra Atoll, Central Pacific. We found growth anomalies (GA) to be the most commonly encountered lesion. Cases of discoloration and tissue loss were rare. GAs had a focal or multi-focal distribution and were predominantly nodular, exophytic, and umbonate. In scleractinians, the majority of GAs manifested as hyperplasia of the basal body wall (52% of cases), with an associated absence or reduction of polyp structure (mesenteries and filaments, actinopharynx and tentacles), and depletion of zooxanthellae in the gastrodermis of the upper body wall. In the soft corals *Sinularia* sp. and *Lobophytum* sp., GAs exclusively manifested as prominent hyperplasia of the coenenchyme with an increased density of solenia. In contrast to scleractinians, soft coral GAs displayed an inflammatory and necrotizing component with marked edema of the mesoglea, accompanied by infiltrates of variably-sized granular amoebocytes. Fungi, algae, sponges, and Crustacea were present in some scleractinian GAs, but absent in soft coral GAs. Fragmentation of tissues was a common finding in *Acropora acuminata* and *Montipora* cf. *dilatata* colonies with tissue loss, although no obvious causative agents were seen. Discoloration in the zoanthid, *Palythoa tuberculosa*, was found to be the result of necrosis, while in *Lobophytum* sp. discoloration was the result of zooxanthellar depletion (bleaching). Soft corals with discoloration or tissue loss showed a marked inflammatory response, however no obvious causative organisms were seen. Lesions that appeared similar at the gross level were revealed to be distinct by microscopy, emphasizing the importance of histopathology.

© 2010 Elsevier Inc. All rights reserved.

1. Introduction

Diseases represent a significant threat to coral reefs worldwide, particularly in the Western Atlantic where widespread disease has resulted in significant declines in coral cover (Nugues, 2002), and phase-shifts from coral- to algal-dominated communities (Aronson and Precht, 2001). Reductions in live coral cover can lead to a loss of coral reef biodiversity (Jones et al., 2004; Idjadi and Edmunds, 2006) and therefore threaten ecosystem function. The presence of a disease within a population results from interactions between the host, causative agent, and environment (Work et al., 2008b). In order to understand disease patterns and processes one must gain insight into each of these three components. The causes of many coral diseases described to date are still unknown; however considerable progress into coral disease etiology has occurred in recent years (Aeby, 1998; Rosenberg et al., 1999; Denner et al., 2003; Richardson, 2004; Cervino et al., 2008; Sussman et al., 2008). Systematic descriptions of gross lesions in corals (Work and Aeby, 2006) in conjunction with histopathology (Peters, 1984) provide an important step towards developing case definitions of diseases and identifying possible causal agents associated with lesions (Work and Rameyer, 2005; Work et al., 2008b).

While histological investigations of some coral diseases, such as growth anomalies (Domart-Coulon et al., 2006; Work et al., 2008a), are becoming more common, many diseases (particularly those affecting soft corals) remain histologically uncharacterized. In addition, no studies have examined diseases occurring at extremely isolated, non-impacted reef systems. Isolated reef systems allow us to examine ecological dynamics and processes in the absence of direct anthropogenic impacts, thus providing critical baseline information under "quasi-pristine" field conditions (Sandin et al., 2008). Palmyra Atoll National Wildlife Refuge represents one of the most isolated and highly protected (from a conservation standpoint) reef systems in the world. Throughout its history, Palmyra has lacked a long-term resident indigenous population. However, during WWII, US military occupation resulted in

* Corresponding author.
E-mail address: simon.davy@vuw.ac.nz (S.K. Davy).
[1] Authors contributed equally to this work.
[2] Present address: Center for Marine Biodiversity and Conservation, Scripps Institution of Oceanography, La Jolla, California, USA.

0022-2011/$ - see front matter © 2010 Elsevier Inc. All rights reserved.
doi:10.1016/j.jip.2010.08.002

several modifications to the atoll including land reclamation, the construction of road causeways and the building of an airstrip (Dawson, 1959). Despite this, and because of its remote location, Palmyra's oceanic reef environment remains largely pristine and functionally intact (Sandin et al., 2008). Nevertheless, coral diseases are apparent at Palmyra (Williams et al., 2008). Using histopathology, we aimed to increase our understanding of lesions in Cnidaria at the cellular level in a relatively pristine reef habitat. Many of our results represent the first histological characterizations of the diseases described.

2. Materials and methods

2.1. Sample collection

Samples were collected from Palmyra Atoll National Wildlife Refuge (05°52′ N, 162°06′ W) in the Central Pacific Ocean during six research trips from 2007 to 2009. Gross lesions were placed into three categories: (1) Discoloration – color change or lack of pigmentation in tissues; (2) Growth anomaly – excessive or apparently uncontrolled growth of skeleton/soft tissues in relation to normal skeleton/tissue on the same individual; (3) Tissue loss – absence of tissues with or without intact skeleton (Work and Aeby, 2006). Tissue loss was labeled as acute if bare white skeleton was exposed, or sub-acute if a progression from bare to alga-covered skeleton was observed. Categories of gross lesions were not mutually exclusive. Samples were collected from 17 species of scleractinian (hard) coral, two species of soft coral (*Lobophytum* sp., *Sinularia* sp.), and a single zoanthid species (*Palythoa tuberculosa*) exhibiting growth anomalies ($n = 65$), tissue loss ($n = 7$), or discoloration ($n = 9$) (Table 1). Samples were collected opportunistically on the forereef, backreef, and western terrace of the atoll, within a depth range of 1–25 m. After photographing the lesion, a paired sample (one healthy tissue sample and one lesion tissue sample on each affected colony) was taken using bone shears or a hammer and chisel, with care taken to collect normal and abnormal tissue bordering the lesion. Samples were then fixed in zinc–formaldehyde solution (Z-Fix, Anatech) diluted 1:5 in ambient non-filtered seawater. For microscopic examination, corals were decalcified using Cal-Ex II (Fisher Scientific), embedded in paraffin, sectioned (at 6 μm), and stained with hematoxylin and eosin.

3. Results

3.1. Gross description – growth anomalies

Growth anomalies had a focal (66% of cases) or multi-focal (34%) distribution, and were nodular (39%), exophytic (25%), umbonate (22%), fimbriate (4%), flat (4%), elongate (3%) or rugose (3%) (Table 2). *Acropora* nodular growth anomalies had chaotically arranged calices that sometimes merged and were overlaid by pale tissue (Fig. 1A). *Astreopora* growth anomalies were exclusively focal and nodular, and consisted of enlarged portions of the coenosteum occurring in protuberant clusters, interspersed with sparse, variably-sized calices overlaid by normally pigmented to pale tissues (Fig. 1B). *Fungia* growth anomalies were exclusively located

Table 1
Microscopic characteristics of gross lesions of Cnidaria at Palmyra Atoll, partitioned by lesion type and host species. For each lesion type, the microscopic characteristics are summarized as an overall proportion of the number of individuals sampled with that type of lesion. (e.g. in 67% of individuals with discoloration the lesion manifested as necrosis).

Lesion type / species	Number colonies sampled	Atrophy	Bleaching	Calicodermal hypertrophy	Fragmentation	HBW	Necrosis	No Lesion
Discoloration								
Acropora digitifera	1				1			
Lobophytum sp.	1		1					
Montipora hoffmeisteri	1						1	
Palythoa tuberculosa	1						1	
Porites pukoensis-stephensoni	1							1
Sinularia sp.	4						4	
Proportion (%)			**11**		**11**		**67**	**11**
Growth anomaly								
Acropora acuminata	1							1
Acropora clathrata	1							1
Acropora cytherea	4					2	1	1
Acropora digitifera	1						1	
Acropora microclados	1					1		
Acropora rosaria	1		1					
Astreopora myriophthalma	8					6		2
Fungia concinna	7			2		1	2	2
Lobophytum sp.	2					2		
Montipora dilitata	1					1		
Montipora cf. *dilatata*	1							1
Montipora efflorescens	22					16	2	4
Montipora foveolata	1					1		
Montipora hoffmeisteri	5					4		1
Pocillopora meandrina	2					1	1	
Porites pukoensis-stephensoni	2					1		1
Porites superfusa	1							1
Sinularia sp.	4					4		
Proportion (%)			**2**	**4**		**61**	**11**	**23**
Tissue loss								
Acropora acuminata	2				2			
Montipora cf. *dilatata*	3				3			
Pocillopora meandrina	2	1					1	
Proportion (%)		**14**			**72**		**14**	

Table 2
Distribution and shape of growth anomalies present among 18 scleractinian and soft coral species at Palmyra Atoll. Described following Work and Aeby (2006).

Species	Number colonies sampled	Distribution of lesion		GA morphology						
		Focal	Multi-focal	Elongate	Exophytic	Fimbriate	Flat	Nodular	Rugose	Umbonate
Scleractinian corals										
Acropora acuminata	1		1		1					
Acropora clathrata	1	1						1		
Acropora cytherea	4	2	2		2	1		1		
Acropora digitifera	1	1						1		
Acropora microclados	1	1			1					
Acropora rosaria	1	1						1		
Astreopora myriophthalma	8	8						8		
Fungia concinna	7	7			2			3	1	1
Montipora dilatata	1		1		1					
Montipora cf. *dilatata*	1	1						1		
Montipora efflorescens	22	11	11		7	1	3	2	1	8
Montipora foveolata	1		1							1
Montipora hoffmeisteri	5	4	1		2			2		1
Pocillopora meandrina	2		2					2		
Porites pukoensis-stephensoni	2	2								2
Porites superfusa	1	1						1		
Soft corals										
Lobophytum sp.	2	1	1			1		1		
Sinularia sp.	4	2	2	2				1		1
Proportion (%)		**66**	**34**	**3**	**25**	**4**	**4**	**39**	**3**	**22**

on the oral disk of the polyp (sometimes covering a large proportion of the mouth) and consisted of nodules covered by coalescing ridges that were, on occasion, overlaid by pink tissue (Fig. 1c). *Montipora* growth anomalies were focal or multi-focal and displayed a wide variety of shapes, generally consisting of either prominent tubercles sometimes coalescing into irregular ridges with fewer polyps (Fig. 1D), or a smoothed coenosteum with lack of polyps overlaid by pale tissues (Fig. 1E and F). *Pocillopora* growth anomalies were exclusively multi-focal and nodular, with lack of calices and overlaid with white tissue (Fig. 2A). *Porites* growth anomalies were exclusively focal and umbonate, and consisted of irregular, raised areas of enlarged calices overlaid by pale tissue (Fig. 2B). The soft corals *Lobophytum* sp. and *Sinularia* sp. exhibited both focal and multi-focal growth anomalies that were predominantly nodular, and characterized by a distinct and pale rugose matrix lacking both polyps and the normal branching morphology (Fig. 2C and D).

3.2. Gross description – discoloration and tissue loss

Among the scleractinian corals, discoloration in *Acropora digitifera* manifested as diffuse, indistinct areas of brown coloration mixed with basally-distributed indistinct areas of white discoloration, and partially pigmented polyps near the edges (Fig. 2E). Discoloration in M*ontipora hoffmeisteri* appeared as a distinct, amorphous raised area of purple discoloration with normal numbers and morphology of polyps (Fig. 2F). In the two soft coral species, *Lobophytum* sp. displayed multi-focal and diffuse irregular areas of white discoloration (Fig. 3A), and *Sinularia* sp. displayed discoloration with associated tissue loss manifested as a localized and diffuse irregular area of black rugose flocculent material, with the coenosarc on occasion becoming overlaid by pale swollen tissue (Fig. 3B). Diffuse white discoloration occurred in the zoanthid *Palythoa tuberculosa* (Fig. 3C). Among the scleractinian corals, *Acropora acuminata* displayed diffuse white areas of acute basal to apical tissue loss across multiple branches (Fig. 3D), while in *Montipora* cf. *dilatata* tissue loss appeared as diffuse areas of ablated skeleton revealing an amorphous smooth area bordered by normal tissues (Fig. 3E). In *Pocillopora meandrina*, diffuse and indistinct areas of chronic tissue loss occurred, mainly at the base of branches (Fig. 3F).

3.3. Histopathology – growth anomalies

The most common overall microscopic finding of growth anomalies was hyperplasia of the basal body wall (61% of cases, $n = 65$) (Table 1). In scleractinian corals, growth anomaly tissue was associated with an absence of polyp actinopharynx and tentacles (47% of cases, $n = 59$), reduced or absent mesenteries and filaments (34%), and depletion of zooxanthellae in the gastrodermis of the upper body wall (31%) (Fig. 4A and B). Among the three most sampled genera (*Acropora*, *Astreopora*, *Montipora*), the percent of growth anomaly cases showing hyperplasia of the basal body wall, lack of polyp structure, and depletion of mesenteries and filaments was higher within *Astreopora* and *Montipora* and lower in *Acropora* (Table 3). Hyperplasia was sometimes associated with microalgae (in two colonies of *Montipora efflorescens* and one colony of *M. hoffmeisteri*) or fungi (one colony of *M. efflorescens*). Growth anomalies associated with Crustacea were most common in *Fungia concinna* (100% of cases, $n = 7$) and one colony of *Pocillopora meandrina*. In *F. concinna*, the crustaceans were exclusively gall crabs (genus *Fungicola*) and were surrounded by filamentous mats of fungi and algae, with the adjacent calicodermis hypertrophied (Fig. 4C and D). Necrosis was seen to be associated with fungi in one colony of *P. meandrina* and one colony of *M. efflorescens*, fungi and sponges in one colony of *M. efflorescens*, and algae in one *F. concinna* colony. Uncomplicated necrosis was seen in one *F. concinna* colony and one colony of *Acropora digitifera*. Depletion of zooxanthellae (bleaching) associated with algae was seen in one colony of *Acropora rosaria*. No microscopic lesions were seen in 14 samples that had been preliminarily identified as growth anomalies in the field.

Growth anomalies in soft corals had prominent hyperplasia of the coenenchyme with an increased density of solenia (100% of cases, $n = 6$) (Table 1, Fig. 4E and F). In contrast to hard corals, soft coral growth anomalies showed a distinct inflammatory and necrotizing component, with marked edema of the mesoglea, exemplified by dilation of connective tissue spaces, accompanied by infiltrates of variably-sized granular amoebocytes. There was also marked hyperplasia and hypertrophy of the gastrodermal cells lining the solenia, with sloughing of cells into the solenial cavity and occasional nidi of laminated hyaline fibrillar material surrounded by gastrodermal cells (Fig. 5**a** and **b**). Pleomorphic or enlarged nuclei and mitotic figures were not seen.



Fig. 1. Growth anomalies on (A) *Acropora clathrata*, (B) *Astreopora myriophthalma*, (C) *Fungia concinna*, (D–F), *Montipora efflorescens*, from Palmyra Atoll, Central Pacific. Arrows (where present) indicate growth anomaly tissue.

3.4. Histopathology – discoloration and tissue loss

Of the scleractinian coral colonies displaying tissue loss ($n = 7$), 72% of cases exhibited tissue fragmentation, with this change observed in *Acropora acuminata* and *M.* cf. *dilatata* (Table 1, Fig. 5**c**). Polychaete worms were embedded in fragmented tissues in *M.* cf. *dilatata*, but not *A. acuminata*. Necrosis, or diffuse atrophy associated with necrosis, was seen in two colonies of *P. meandrina*. One *M. hoffmeisteri* colony had a raised area of discoloration that, on histological examination, revealed invasion of tissues by sponges and fungi associated with mild infiltrates of eosinophilic granular amoebocytes (Fig. 5**d**). Of the species exhibiting discoloration ($n = 9$), 67% of cases showed evidence of necrosis (Table 1). Tissue fragmentation was seen in one colony of *A. digitifera*, while one colony of *Lobophytum* sp. had lost zooxanthellae from its gastrodermal cells. One colony of *Palythoa tuberculosa* with discoloration showed evidence of necrosis, while necrosis often accompanied by marked infiltrates of eosinophilic granular amoebocytes was seen in all *Sinularia* sp. colonies exhibiting discoloration ($n = 4$) (Fig. 5**e** and **f**).

4. Discussion

Overall, growth anomalies were the most commonly encountered lesion on the reefs at Palmyra Atoll, affecting 18 species (representing eight genera) of scleractinian and soft corals. Growth anomalies on scleractinian corals are commonly reported (Suther-



Fig. 2. Growth anomalies on (A) *Pocillopora meandrina*, (B) *Porites pukoensis-stephensoni* (arrow indicates growth anomaly tissue), (C) *Lobopyhtum* sp., and (D) *Sinularia* sp., tissue loss in (E) *Acropora digitifera* (arrow indicates tissue loss which appears white with brown discoloration in places), and discoloration in (F) *Montipora hoffmeisteri*, from Palmyra Atoll, Central Pacific.

land et al., 2004) and widespread throughout the Central Pacific (Work et al., 2008a; Vargas-Angel, 2009). In contrast, reports of tumor-like growths in octocorals are rare (Morse et al., 1981; Weil et al., 2006), and our findings from Palmyra represent the first report and histological examination of soft coral growth anomalies (and indeed many newly described scleractinian coral lesions) from the Central Pacific.

Generally, the microscopic morphology of growth anomalies in scleractinians from Palmyra was similar to that of acroporid corals in American Samoa, Johnston Atoll and French Frigate Shoals in the northwestern Hawaiian Islands (Work et al., 2008a) and Japan (Yamashiro et al., 2000); namely hyperplasia of the basal body wall, reduced or absent polyp formation, and depletion of mesenteries and filaments and zooxanthellae. No obvious causative agents were seen, however a viral etiology cannot be ruled out, and confirming this would, at the very least, require examination of tissues at the ultra-structural level and molecular assays showing the presence of viruses in growth anomaly but not in normal tissues. Viruses are a natural component of the coral holobiont (Vega Thurber et al., 2009) but are associated with tumor disease in other marine organisms, such as fibropapillomatosis (tumors) in marine turtles (Work et al., 2001). In contrast, *Fungia concinna* growth anomalies at Palmyra appear to be caused by the presence of the gall crab *Fungicola* sp. Gall crabs are well known to disrupt scleractinian coral skeletogenesis (Carricart-Ganivet et al., 2004; Johnsson et al., 2006) and several species have been documented



Fig. 3. Discoloration in (A) *Lobophytum* sp., (B) *Sinularia* sp. (arrow indicates discoloration), and (C) *Palythoa tuberculosa*, and tissue loss in (D) *Acropora acuminata* (white arrow indicates healthy tissue, black arrow indicates area of tissue loss which appears white), (E) *Montipora* cf. *dilatata* and (F) *Pocillopora meandrina* (white arrow indicates healthy tissue, black arrow indicates area of tissue loss which appears white), from Palmyra Atoll, Central Pacific.

in fungiids from the Pacific (Kropp, 1990). These findings highlight the fact that gross lesions in scleractinian corals may appear similar in the field but distinct when examined by microscopy, thus emphasizing the importance of histological examination in coral disease investigations.

As in scleractinian corals, growth anomalies in soft corals were associated with hyperplasia of the coenenchyme and proliferation of the solenia; however, soft corals were distinguished from scleractinians by exhibiting a marked inflammatory response consisting of an edema of the mesoglea, infiltrates of mesogleal cells, and hypertrophy, pleomorphism and hyperplasia of the gastrodermal cells. The presence of laminated cores of hyaline membranes surrounded by mesogleal cells was somewhat reminiscent of hyaline membrane deposition seen in growth anomalies of *Acropora* spp. in American Samoa (Work et al., 2008a). In *Acropora* spp., growth anomalies have been shown to spread and lead to chronic loss of tissues (Work et al., 2008a). Temporal studies remain to be performed for soft corals; however the marked inflammation of growth anomaly tissues indicates a strong host response with attendant detrimental effects to the tissues. Unlike scleractinian corals, organisms such as fungi, algae, sponges and crustaceans were not present in soft coral growth anomalies. As with scleractinian corals (Work et al., 2008a), it is presently unclear whether growth anomalies in soft corals are true cancers or a temporary process that is reversible. Although the cellular pleomorphism seen in the gastrodermal cells was suggestive of neoplasia, additional studies, perhaps by monitoring colonies over time, may shed more light on the development and fate of growth anomalies in soft corals.

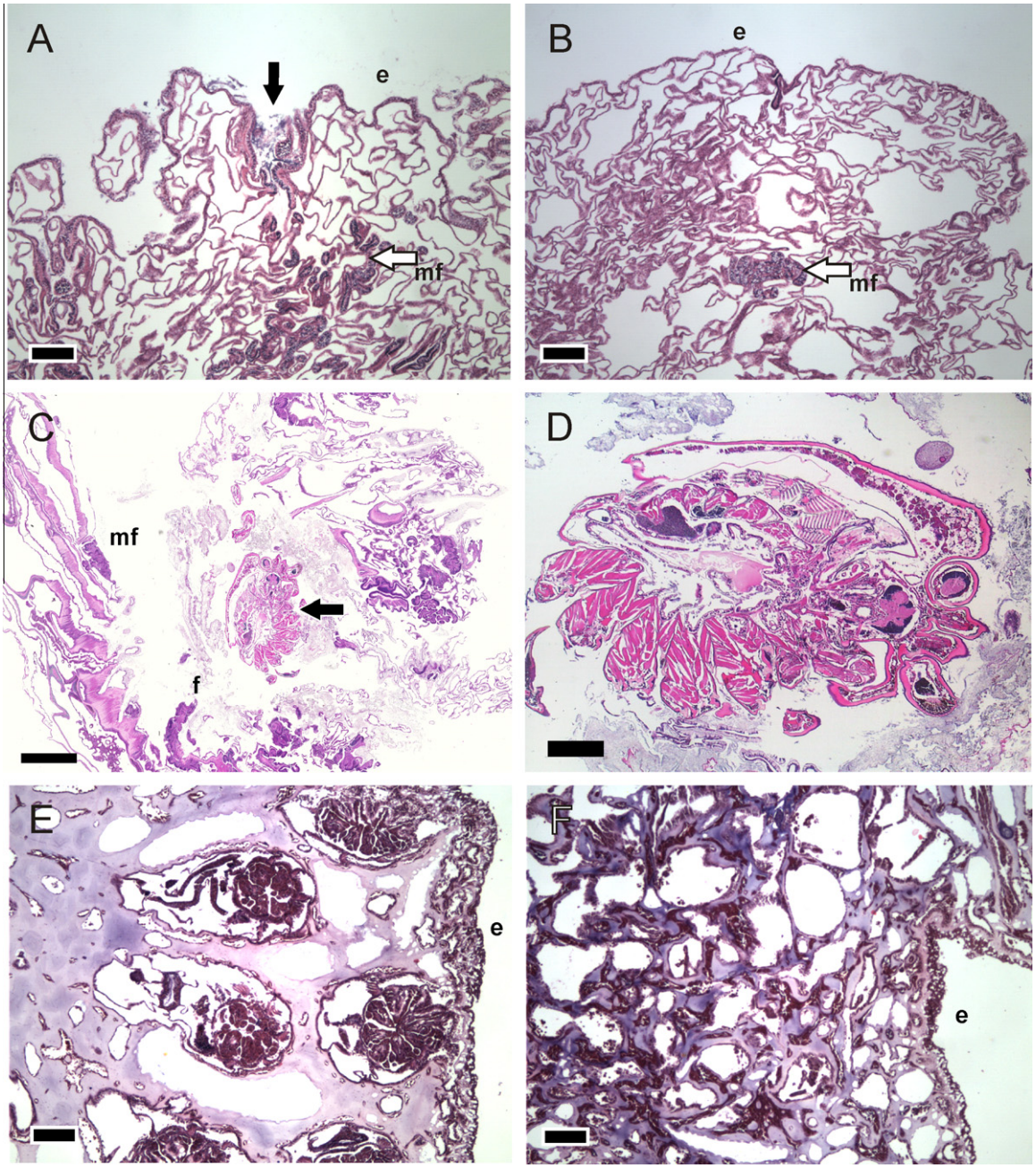

Fig. 4. (A) Normal *Montipora efflorescens*. Note development of polyp (black arrow) and mesenteries and filaments (white arrow); bar = 300 μm. (B) *M. efflorescens* with hyperplasia of basal body wall. Note absence of polyp structure and small mesenteries and filaments (white arrow); bar = 300 μm. (C) *Fungia concinna* growth anomaly. Note gall crab *in situ* (black arrow); bar = 2 mm. (D) Close up of crab in A; bar = 0.5 mm. (E) Normal *Sinularia* sp. Note regular organization of polyps; bar = 300 μm. (F) *Sinularia* sp. growth anomaly. Note proliferation of coenenchyme and solenia with lack of polyp structure; bar = 300 μm. e, epidermis; mf, mesenteries and filaments; f, fungus.

Fragmentation of tissues was a common finding for scleractinian coral tissue loss at Palmyra; however, again no obvious causative agents were seen, including intra-cytoplasmic or intra-nuclear inclusions suggestive of viral replication. The etiologies for the majority of tissue loss diseases in scleractinian corals remain unknown (Sutherland et al., 2004). Presence of polychaetes associated with tissue fragmentation in *M.* cf. *dilatata* suggested that, in these cases, tissue loss could be the result of predation by these worms, not disease, once again highlighting the importance of histological examination in coral disease investigations.

Table 3
Percentages of growth anomaly cases exhibiting hyperplasia of the basal body wall (HBW), lack of a defined polyp structure, depletion/absence of mesentries and filaments (reduced MF), and depletion/absence of zooxanthellae in the gastrodermal cells (reduced zoox), in three scleractinian coral genera from Palmyra Atoll. Number of growth anomalies sampled for each genus shown in parentheses.

Genus	HBW	Lack of polyp	Reduced MF	Reduced zoox
Acropora (9)	33	44	33	33
Astreopora (8)	75	63	63	38
Montipora (30)	73	53	47	43

Diseases appear to be a natural component of tropical coral reefs, even under quasi-pristine conditions. At Palmyra, growth anomalies on scleractinian corals were commonly encountered (particularly on *Montipora* spp.), whereas growth anomalies on soft corals, tissue loss diseases, and cases of discoloration were rare.

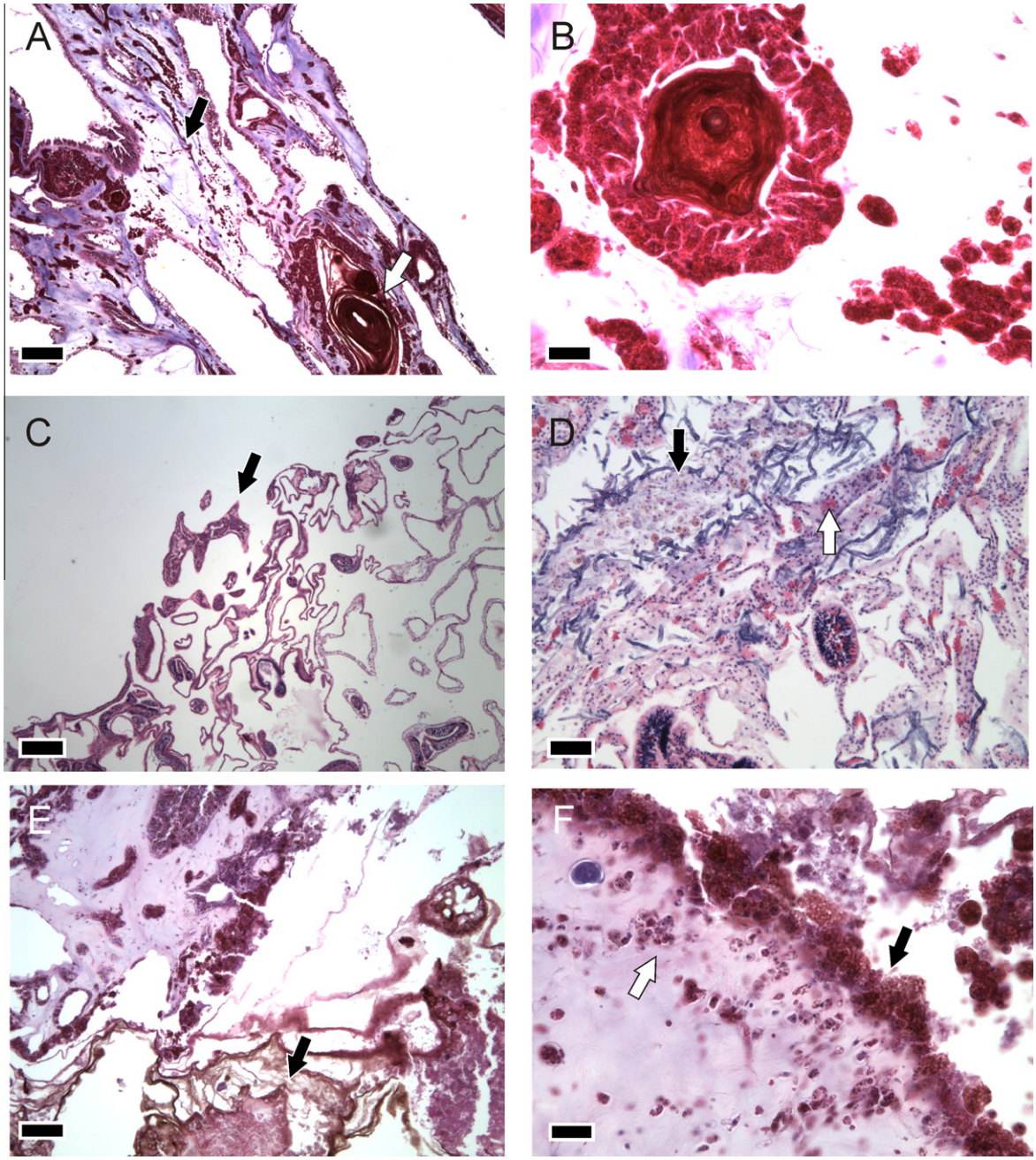

Fig. 5. (A) Growth anomaly in *Sinularia* sp. Note marked edema of the mesoglea with infiltrates of amoebocytes (black arrow) and nidus of eosinophilic laminated debris surrounded by gastrodermal cells within lumen of solenia (white arrow), bar = 300 μm. (B) Close up of laminated hyaline material surrounded by variably-sized pleomorphilic gastrodermal cells; bar = 20 μm. (C) *Pocillopora meandrina* with tissue loss. Note fragmentation of tissues (black arrow); bar = 50 μm. (D) *Montipora hoffmeisteri* with raised area of discoloration. Note invasion of sponge (black arrow) mixed with fungal hyphae (dark filaments) accompanied by granulocytic amoebocytes (white arrow); bar = 50 μm. (E) Necrosis in *Sinularia* sp. Note debris mixed with clumps of hyaline membranous material (black arrow), bar = 300 μm. (F) Close up of inflammatory response to necrosis in *Sinularia* sp. Note proliferation of gastrodermal cells (black arrow) and marked infiltrates of amoebocytes within mesoglea (white arrow); bar = 20 μm.

While the overall prevalence of coral diseases at Palmyra may be low (Williams et al., 2008; Vargas-Angel, 2009), certain scleractinian genera appear particularly susceptible (for example *Montipora* spp.). Our results suggest an overall detrimental effect of growth anomalies on the coral hosts at Palmyra, perhaps via a lack of polyp formation and therefore an inability for the growth anomaly tissue to feed. Histological manifestations of growth anomalies from a remote, isolated, quasi-pristine reef mimic those from more impacted reefs and the potential threat of these growth anomalies, as well as the rare cases of tissue loss and discoloration diseases, to reef health and function at Palmyra require further study. Efforts should focus on determining the fate and progression of these diseases and their associations with the environment, as well as examining lesions at the ultra-structural and molecular levels to investigate the possible involvement of viral causative agents.

Acknowledgments

We thank the US Fish and Wildlife Service and The Nature Conservancy for granting access to the refuge and logistical support. Thanks also to Jim Maragos for assistance with cnidarian taxonomy, and Scott Godwin for assistance with gall crab taxonomy.

Lastly, we thank two anonymous referees who critically reviewed the manuscript. This work was funded, in part, by a Grant from the National Geographic Society awarded to SKD. GJW was supported by a Victoria University of Wellington Vice-Chancellor's Strategic Research Scholarship and a New Zealand International Doctoral Research Scholarship. Victoria University of Wellington and USGS are members of the Palmyra Atoll Research Consortium (PARC). The majority of this work was conducted under the special use permit 12533-09015 granted by the United States Department of the Interior Fish and Wildlife Service.

References

Aeby, G.S., 1998. A digenean metacercaria from the reef coral, *Porites compressa*, experimentally identified as *Podocotyloides stenometra*. J. Parasitol. 84, 1259–1261.

Aronson, R.B., Precht, W.F., 2001. White-band disease and the changing face of Caribbean coral reefs. Hydrobiologia 460, 25–38.

Carricart-Ganivet, J.P., Carrera-Parra, L.F., Quan-Young, L.I., Garcia-Madrigal, M.S., 2004. Ecological note on *Troglocarcinus corallicola* (Brachyura : Cryptochiridae) living in symbiosis with *Manicina areolata* (Cnidaria : Scleractinia) in the Mexican Caribbean. Coral Reefs 23, 215–217.

Cervino, J.M., Thompson, F.L., Gomez-Gil, B., Lorence, E.A., Goreau, T.J., Hayes, R.L., Winiarski-Cervino, K.B., Smith, G.W., Hughen, K., Bartels, E., 2008. The *Vibrio* core group induces yellow band disease in Caribbean and Indo-Pacific reef-building corals. J. Appl. Microbiol. 105, 1658–1671.

Dawson, E.Y., 1959. Changes in Palmyra Atoll and its vegetation through the activities of man 1913–1958. Pacific Naturalist 1, 1–51.

Denner, E.B.M., Smith, G.W., Busse, H.J., Schumann, P., Narzt, T., Polson, S.W., Lubitz, W., Richardson, L.L., 2003. *Aurantimonas coralicida* gen. nov., sp. nov., the causative agent of white plague type II on Caribbean scleractinian corals. Int. J. Syst. Evol. Microbiol. 53, 1115–1122.

Domart-Coulon, I.J., Traylor-Knowles, N., Peters, E., Elbert, D., Downs, C.A., Price, K., Stubbs, J., McLaughlin, S., Cox, E., Aeby, G., Brown, P.R., Ostrander, G.K., 2006. Comprehensive characterization of skeletal tissue growth anomalies of the finger coral *Porites compressa*. Coral Reefs 25, 531–543.

Idjadi, J.A., Edmunds, P.J., 2006. Scleractinian corals as facilitators for other invertebrates on a Caribbean reef. Mar. Ecol. Prog. Ser. 319, 117–127.

Johnsson, R., Neves, E., Franco, G.M.O., da Silveira, F.L., 2006. The association of two gall crabs (Brachyura: Cryptochiridae) with the reef-building coral *Siderastrea stellata* Verrill, 1868. Hydrobiologia 559, 379–384.

Jones, G.P., McCormick, M.I., Srinivasan, M., Eagle, J.V., 2004. Coral decline threatens fish biodiversity in marine reserves. PNAS 101, 8251–8253.

Kropp, R.K., 1990. Revision of the genera of gall crabs (Crustacea: Cryptochiridae) occurring in the Pacific Ocean. Pacific Sci. 44, 417–448.

Morse, D.E., Morse, A., Duncan, H., Trench, R.K., 1981. Algal tumors in the Caribbean octocorallian, *Gorgonia ventalina*: II Biochemical characterization of the algae, and first epidemiological observations. Bull. Mar. Sci. 31, 399–409.

Nugues, M.M., 2002. Impact of a coral disease outbreak on coral communities in St. Lucia: what and how much has been lost? Mar. Ecol. Prog. Ser. 229, 61–71.

Peters, E.C., 1984. A survey of cellular reactions to environmental stress and disease in Caribbean scleractinian corals. Helgolander Meeres 37, 113–137.

Richardson, L.L., 2004. Black band disease. In: Rosenberg, E., Loya, Y. (Eds.), Coral Health and Disease. Springer-Verlag, Berlin, pp. 325–336.

Rosenberg, E., Ben-Haim, Y., Toren, A., Banin, E., Kushmaro, A., Fine, M., Loya, Y., 1999. Effect of temperature on bacterial bleaching of corals. In: Rosenberg, E. (Ed.), Microbial Ecology and Infectious Disease. American Society for Microbiology, Washington, DC, pp. 242–254.

Sandin, S.A., Smith, J.E., DeMartini, E.E., Dinsdale, E.A., Donner, S.D., Friedlander, A.M., Konotchick, T., Malay, M., Maragos, J.E., Obura, D., Pantos, O., Paulay, G., Richie, M., Rohwer, F., Schroeder, R.E., Walsh, S., Jackson, J.B.C., Knowlton, N., Sala, E., 2008. Baselines and degradation of coral reefs in the northern Line Islands. PLoS ONE 3, e1548.

Sussman, M., Willis, B.L., Victor, S., Bourne, D.G., 2008. Coral pathogens identified for white syndrome (WS) epizootics in the Indo-Pacific. PLoS ONE 3, e2393.

Sutherland, K.P., Porter, J.W., Torres, C., 2004. Disease and immunity in Caribbean and Indo-Pacific zooxanthellate corals. Mar. Ecol. Prog. Ser. 266, 273–302.

Vargas-Angel, B., 2009. Coral health and disease assessment in the US Pacific Remote Island Areas. Bull. Mar. Sci. 84, 211–227.

Vega Thurber, R., Willner-Hall, D., Rodriguez-Mueller, B., Desnues, C., Edwards, R.A., Angly, F., Dinsdale, E., Kelly, L., Rohwer, F., 2009. Metagenomic analysis of stressed coral holobionts. Environ. Microbiol. 11, 2148–2163.

Weil, E., Smith, G., Gil-Agudelo, D.L., 2006. Status and progress in coral reef disease research. Dis. Aquat. Org. 69, 1–7.

Williams, G.J., Aeby, G.S., Davy, S.K., 2008. Coral disease at Palmyra Atoll, a remote reef system in the Central Pacific. Coral Reefs 27, 207.

Work, T.M., Aeby, G.S., 2006. Systematically describing gross lesions in corals. Dis. Aquat. Org. 70, 155–160.

Work, T.M., Rameyer, R.A., 2005. Characterizing lesions in corals from American Samoa. Coral Reefs 24, 384–390.

Work, T.M., Rameyer, R.A., Balazs, G.H., Cray, C., Chang, S.P., 2001. Immune status of free-ranging green turtles with fibropapillomatosis from Hawaii. J. Wildl. Dis. 37, 574–581.

Work, T.M., Aeby, G.S., Coles, S.L., 2008a. Distribution and morphology of growth anomalies in *Acropora* from the Indo-Pacific. Dis. Aquat. Org. 78, 255–264.

Work, T.M., Richardson, L.L., Reynolds, T.L., Willis, B.L., 2008b. Biomedical and veterinary science can increase our understanding of coral disease. J. Exp. Mar. Biol. Ecol. 362, 63–70.

Yamashiro, H., Yamamoto, M., van Woesik, R., 2000. Tumor formation on the coral *Montipora informis*. Dis. Aquat. Org. 41, 211–217.