Provided for non-commercial research and education use.
Not for reproduction, distribution or commercial use.

This article appeared in a journal published by Elsevier. The attached copy is furnished to the author for internal non-commercial research and education use, including for instruction at the authors institution and sharing with colleagues.

Other uses, including reproduction and distribution, or selling or licensing copies, or posting to personal, institutional or third party websites are prohibited.

In most cases authors are permitted to post their version of the article (e.g. in Word or Tex form) to their personal website or institutional repository. Authors requiring further information regarding Elsevier's archiving and manuscript policies are encouraged to visit:

http://www.elsevier.com/authorsrights

Author's personal copy

Journal of Invertebrate Pathology 117 (2014) 42–50

Contents lists available at ScienceDirect

Journal of Invertebrate Pathology

journal homepage: www.elsevier.com/locate/jip

Lectins stain cells differentially in the coral, *Montipora capitata*

Thierry M. Work [a,*], Yael Farah [b]

[a] U.S. Geological Survey, National Wildlife Health Center, Honolulu Field Station, PO Box 50167, Honolulu, HI 96850, USA
[b] University of Illinois, School of Veterinary Medicine, Urbana Champaign, IL 61820, USA

ARTICLE INFO

Article history:
Received 29 June 2013
Accepted 31 January 2014
Available online 8 February 2014

Keywords:
Histopathology
Lectins
Coral
Montipora capitata

ABSTRACT

A limitation in our understanding of coral disease pathology and cellular pathogenesis is a lack of reagents to characterize coral cells. We evaluated the utility of plant lectins to stain tissues of a dominant coral, *Montipora capitata*, from Hawaii. Of 22 lectins evaluated, nine of these stained structures in the upper or basal body wall of corals. Specific structures revealed by lectins that were not considered distinct or evident on routine hematoxylin and eosin sections of coral tissues included apical and basal granules in gastrodermis and epidermis, cnidoglandular tract and actinopharynx cell surface membranes, capsules of mature holotrichous isorhizas, and perivitelline and periseminal cells. Plant lectins could prove useful to further our understanding of coral physiology, anatomy, cell biology, and disease pathogenesis.

Published by Elsevier Inc.

1. Introduction

Climate change and land use patterns are contributing to declines of coral reefs globally (Hoegh-Guldberg, 1999; Waddell and Clarke, 2008). As this trend continues, diseases that have caused marked declines of corals in the western Atlantic (Green and Bruckner, 2000) will play an increasingly important role both there and in the Pacific (Willis et al., 2004). In recognition of this, increasing efforts are being made to understand potential causes of coral diseases. At the same time, the number of diseases documented continues to increase (Sutherland et al., 2003).

Pathology at the gross and microscopic level is routinely analyzed to assist in understanding causes and pathogenesis of various animal diseases (Cheville, 1988). When applied to corals, histopathology can yield objective data on organisms associated with cell pathology and host response to those organisms, thus potentially guiding subsequent laboratory investigations (Work et al., 2012). On standard hematoxylin and eosin sections, recognizable cell types in corals include zooxanthellae, gastrodermal cells, calicodermal cells, epidermal cells, epitheliomuscular cells, myonemes, nematocysts, mucocytes, granular gland cells, amoebocytes, supporting cells, calicodermis, and neurons; the latter are rarely visualized in light microscopy sections (Fautin and Mariscal, 1991; Galloway et al., 2006; Hyman, 1940). We suspect, however, that these cell types are not monotypic populations, but could involve multiple different subtypes not readily resolvable on standard light microscopy of hematoxylin and eosin stained tissue sections.

Developing markers to identify particular cell types in corals could shed light on our understanding of coral development, anatomy, and pathology. For instance, before the advent of specific protein markers, lectins were used to separate bone marrow cell types in mice (Reisner et al., 1978). Unfortunately, attempts to isolate coral cells are generally limited to cell clusters (Kopecky and Ostrander, 1999), and aside from separating coral tissues from zooxanthellae, there are currently no reliable techniques to separate individual coral cells. This complicates the development of cell-specific protein markers such as monoclonal antibodies. The problem faced by coral pathologists is similar to those studying cellular biology of tumors before cell-specific protein and molecular markers were available. At the time, the use of lectins (plant proteins that attach to particular sugar molecules on cell membranes) was a conceptual step forward in helping us understand tumor biology. For example, aberrant glycosylation as detected by certain lectins was considered a marker of metastasis in certain cancers (Damjanov, 1987).

Our objective was to evaluate the utility of lectins to label cells of the coral, *Montipora capitata*.

2. Methods

2.1. Tissue processing

Fragments from an apparently healthy colony of *M. capitata* originating from Kaneohe Bay, Hawaii, were collected, immediately

* Corresponding author. Fax: +1 808 792 9596.
E-mail address: Thierry_work@usgs.gov (T.M. Work).

http://dx.doi.org/10.1016/j.jip.2014.01.008
0022-2011/Published by Elsevier Inc.

Author's personal copy

Table 1
Plant or animal species from which lectins originated partitioned by sugar family, abbreviation of lectin, whether lectin was useful (Yes/No) to detect anatomical structures in *Montipora capitata*, concentrations used (μg/ml), inhibitory sugars and concentration (M). For useful lectins, optimal concentration only is listed. Incubation time for all inhibitory sugars was 1 h except for PHA (16 h).

Lectin	Abbrev.	Useful?	μg/ml	Sugar (M)
Fucose				
Ulex europaeus (Gorse)	UEA	Y	50	L-Fucose (0.1)
Mannose				
Concanavalin A (Jack bean)	ConA	N	10–100	
Lens culinaris (Lentil)	LCA	N	5–10	
Pisum sativum (Pea)	PSA	N	5–10	
N-Acetylgalactosamine				
Arachis hypogaea (Peanut)	PNA	Y	5	Galactose (0.2)
Dolichos biflorus (Horse gram)	DBL	N	10–100	
Glycine max (Soybean)	SBA	N	1–10	
Griffonia simplicifolia I (Griffonia)	GSL1	Y	10	Galactose (0.2) + N-acetyl-galactosamine (0.2)
Saphora japonica (Japanese pagoda)	SJA	Y	10	N-acetylgalactosamine (0.1)
Vicia villosa (Hairy vetch)	VVL	N	1–100	
N-acetylglucosamine				
Artocarpus integrifolia (Jacalin)	JAC	N	10	
Datura stramonium (Jimson weed)	DSL	N	1–10	
Erythrina cristagalli (Coral tree)	ECL	N	5–10	
Griffonia simplicifolia II (Griffonia)	GSL2	Y	1	N-acetylglucosamine (0.2)
Lycopersicon esculentum (Tomato)	LEA	Y	1	N-acetylglucosamine (0.4)
Phaseolus vulgaris-E (Bean)	PHA-E	Y	1	Galactose (0.4) + N-acteylglucosamine (0.2) + N-acetylgalactosamine(0.4) + Mannose (0.2) + α-Methyl glucoside (0.4) + α-Methyl mannoside (0.4)
Phaseolus vulgaris-L (Bean)	PHA-L	Y	50	Galactose (0.4) + N-acteylglucosamine (0.2) + N-acetylgalactosamine(0.4) + Mannose (0.2) + α-Methyl glucoside (0.4) + α-Methyl mannoside (0.4)
Ricinus communis (Castor bean)	RCA	N	5–10	
Solanum tuberosum (Potato)	STL	Y	5	N-acetylglucosamine (0.4)
Triticum vulgaris (Wheat)	WGA	N	1–10	
Triticum vulgaris-succinylated (Wheat Germ)	sWGA	N	0.5–10	
Sialic acid				
Limax flavus (Slug)	LFA	N	10	Sialic acid (0.1)

Table 2
Anatomical structures of *Montipora capitata* stained with 10 useful lectins (see Table 1 for abbreviations), sugar family, and staining quality (blank-no, w-weak, s-strong staining). Structures are partitioned between upper body wall (actinopharynx, ceonenchyme) and basal body wall (mesenterial filaments, ova, spermaries). Total for upper and basal body wall refer to number of structures in each compartment stained by particular lectin. Row totals are number of lectins staining particular structure with total for upper and basal body wall indicating number of structures examined for each compartment (17 and 15). Structures with asterisk are those not readily visualized on routine hematoxylin and eosin.

	Fucose	N-acetyl-galactosamine			N-acetylglucosamine					
Anatomical structure	UEA1	GSL1	PNA	SJA	GSL2	LEA	STL	PHA-E	PHA-L	TOTAL
Upper body wall-Coenenchyme										
Epidermal gland cells		s								1
Epidermal mucocytes	w		s		s		w	w	s	6
Epidermal granules*			s							1
Mesoglea	s	s		w				s		4
Gastrodermis cytoplasm			s							1
Gastrodermis zooxanthellae		s			w					2
Gastrodermis basal granules*									s	1
Calicodermis		w				s	s			3
Upper body wall-Actinopharynx										
Epidermal gland cells		s	s	s	s	s	s	s	s	8
Epidermal spirocyst									s	1
Epidermal apical granules*			s							1
Epidermal apical cytoplasm and cilia*	s									1
Mesoglea	s	s							s	3

(*continued on next page*)

Author's personal copy

Table 2 (*continued*)

	Fucose	N-acetyl-galactosamine			N-acetylglucosamine					
Gastrodermis zooxanthellae		s								1
Gastrodermis basal granules*			s			s				2
Total Upper body wall	4	7	6	2	3	3	3	3	5	17
Basal body wall-Mesenterial filaments										
Nematocyst-Mature	s	s			w	w	s	w	w	7
Nematocyst-mature capsule*			s							1
Cnidoglandular tract granular gland cells		s	s	w	s	s	s		s	7
Reticular/ciliary tract		s	s		s		s	s	w	6
Cnidoglandular tract cell surface membrane*	s									1
Calicodermis		w			w	s	s	w		5
Basal body wall-Oocytes										
Yolk		s			s					2
Perivitelline space*								s		1
Perivitelline cells basal granules*						s				1
Perivitelline cell cytoplasm*			s							1
Perivitelline cell basal lamina*									s	1
Basal body wall-spermaries										
Sperm					s					1
Periseminal cells basal lamina*									s	1
Periseminal stroma		s			s		s			3
Periseminal cells basal granules*						s	s			2
Periseminal cells cytoplasm*			s							1
Calicodermis							s	w		2
Total basal body wall	2	6	4	1	7	5	6	4	5	15

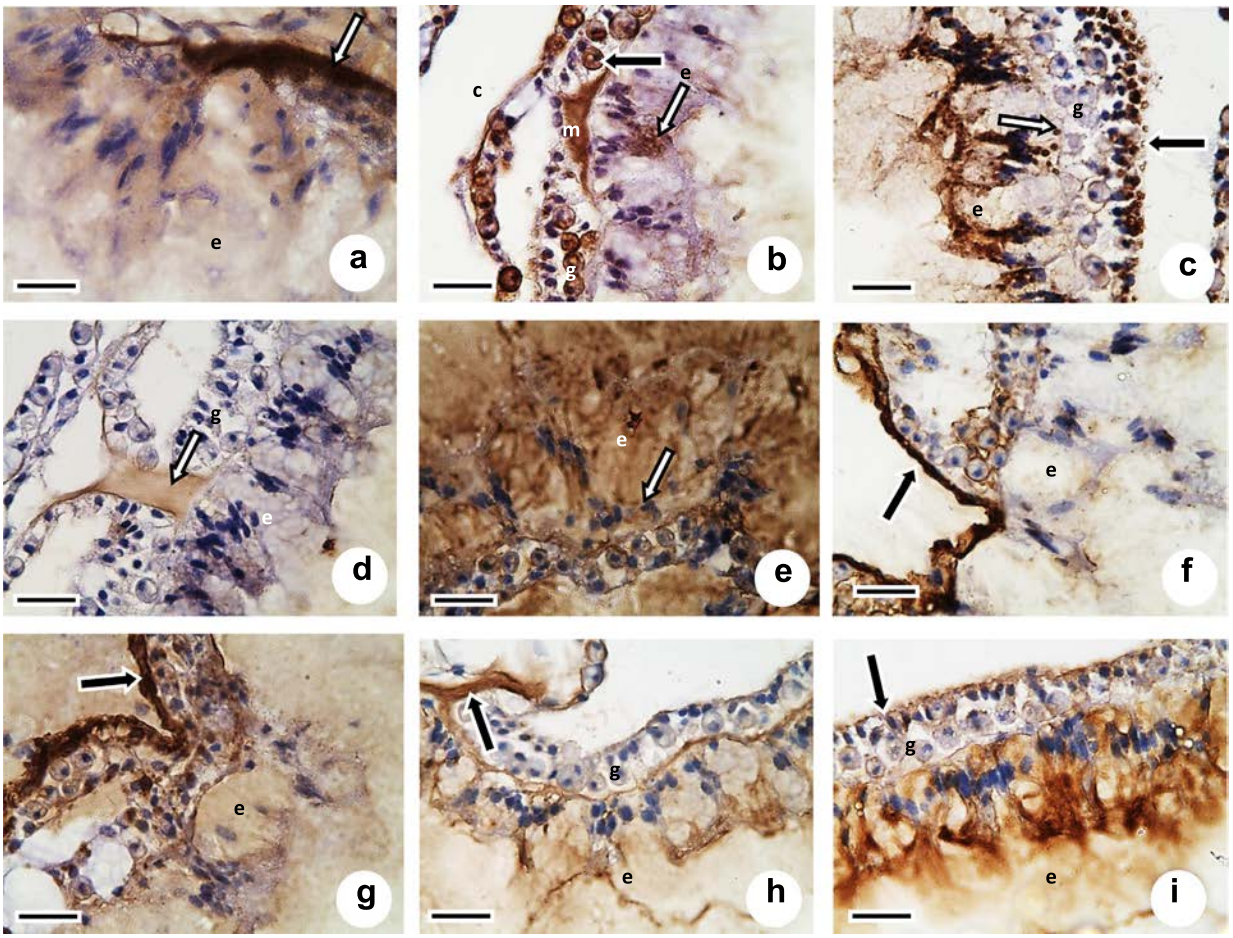

Fig. 1. Upper body wall. (a) *Ulex europaeus* (UEA)-note strong staining of mesoglea (arrow) and weak staining of epidermal cells. (b) *Griffonia simplicifolia* I (GSL-1)-note strong staining of zooxanthellae (black arrow), mesoglea, and epidermal granular gland cells (white arrow), and weak staining of calicodermis. (c) *Arachis hypogaea* (PNA)-note staining of gastrodermal cells (black arrow), superficial epidermal mucosa, and basal granules in epidermis (white arrow). (d) *Saphora japónica* (SJA)-Note weak staining of mesoglea (arrow). (e) *Griffonia simplicifolia* II (GSL-II)-note strong staining of epidermis and weak staining of zooxanthellae (arrow). (f) *Lycopersicon esculentum* (LEA)-Note strong staining of calicodermis (arrow). (g) *Solanum tuberosum* (STL)-note strong staining of calicodermis (arrow) and weak staining of epidermal mucocytes. (h) *Phaseolus vulgaris*-E (PHA-E)-note strong staining of mesoglea (arrow) and weak staining of superficial epidermis. (i) *Phaseolus vulgaris*-L (PHA-L)-Note staining of basal portion of gastrodermis (arrow) and epidermal cells. e = epidermis, g = gastrodermis, m = mesoglea, bar = 20 μm for all photos.

Author's personal copy

fixed in zinc-formaldehyde (Z-Fix, Anatech, Battle Creek, MI), decalcified in 10% EDTA, and processed for paraffin embedding and sectioning at 5 μm.

Tissues were deparaffinized and hydrated using a graded series of xylene (3 min), 100% (4 min) and 95% (1 min), deinonized water (2 min) and equilibration in lectin buffer (0.05 M Tris base, 0.15 M NaCl, 2 mM MgCl2, 1 mM $CaCl_2$) (Brooks et al., 1996). For detection of peanut agglutinin (PNA), Phytohaemagglutinin A-E (PHA-E) and PHA-L, antigens were retrieved for 5 min with Proteinase K (DAKO) and washed with lectin buffer three times, 1 min each, followed by a water rinse (three times, 1 min each). To block endogenous avidin activity, tissues were incubated 15 min with raw egg white, rinsed once with distilled water, and rinsed three times with lectin buffer. To block endogenous biotin, tissues were incubated with 2% nonfat powdered milk in lectin buffer and subsequently rinsed with water and lectin buffer as for avidin block. Tissues were then incubated for 1 h in biotinylated lectin with optimal concentration determined empirically by evaluating progressive decreasing or increasing concentrations to minimize background and optimize signal to noise ratio (Table 1). After three washes in lectin buffer and one rinse in distilled water, tissues were incubated for 30 min with 5 μg/ml streptavidin–peroxidase diluted in lectin buffer (Sigma, Columbia, Missouri, USA), rinsed once in water, three times in lectin buffer, and incubated for 30 s with diaminobenzidine (DAKO, Carpinteria, California, USA). Tissues were rinsed once in water, counterstained for 30 s with hematoxylin (DAKO) as per manufacturer instructions, and rinsed 10 times in tap water. Tissues were then dehydrated by incubating 1 min each in 95% and 100% ethanol followed by 1 min in xylene and coverslipped with cytoseal (Thermo Fisher, Waltham, Massachusetts, USA). Controls included incubation of tissues with lectins pre-incubated with their respective conjugate sugars dissolved in lectin buffer to appropriate concentration (Table 1) prior to incubation with tissues; successful negative controls were tissues revealing no staining with pre-incubated lectins (Brooks et al., 1996).

2.2. Interpretation of staining patterns

Coral tissues were divided into the following compartments: Upper body wall comprised the coenenchyme and polyp actinopharynx; the basal body wall included mesenterial filaments, ova and spermaries. Recognizable cell types or anatomical structures

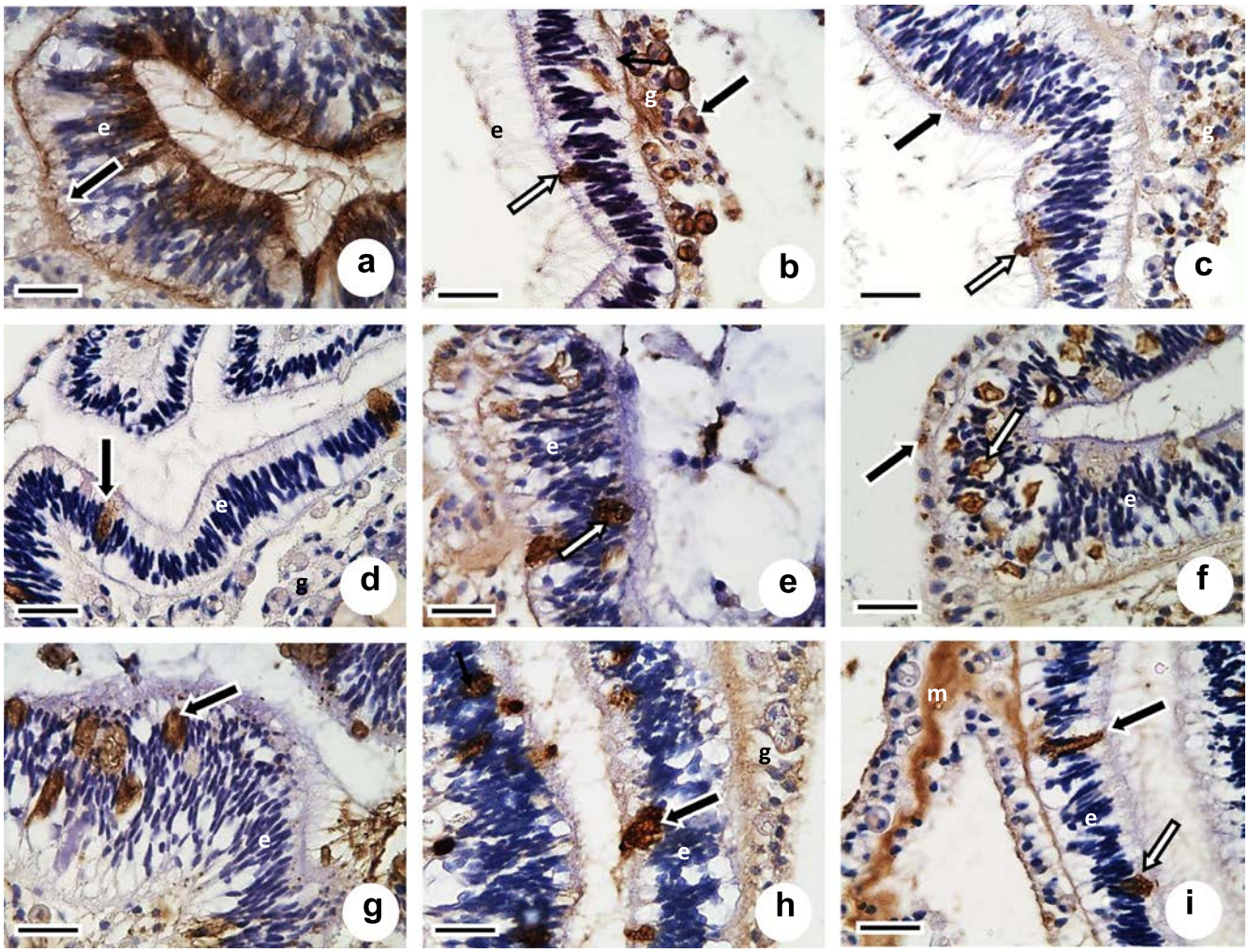

Fig. 2. *Montipora capitata* actinopharynx. (a) *Ulex europaeus* (UEA)-note strong staining of superficial portion of epidermis along with ciliae and mesoglea (arrow). (b) *Griffonia simplicifolia* I (GSL-1)-note strong staining of zooxanthellae (black arrow), mesoglea, and epidermal granular gland cells (white arrow). (c) *Arachis hypogaea* (PNA)-note tiny brown granules in superficial epidermis (black arrow), granular gland cells (white arrow) and brown granules in gastrodermis. (d) *Saphora japónica* (SJA)-Note brown granular gland cells in epidermis (arrow). (e) *Griffonia simplicifolia* II (GSL-II)-note strong staining of granular gland cells in columnar epidermis (arrow). (f) *Lycopersicon esculentum* (LEA)-Note strong staining of angular granular gland cells surrounded by vacuole (white arrow) and isolated brown inclusions in gastrodermis (black arrow). (g) *Solanum tuberosum* (STL)-note strong staining of granular gland cells in epidermis (arrow). (h) *Phaseolus vulgaris*-E (PHA-E)-note brown granular gland cells in epidermis (arrow). (i) *Phaseolus vulgaris*-L (PHA-L)-Note staining of spirocyst (black arrow) and granular gland cell (white arrow) in epidermis. e = columnar epidermis of actinopharynx, g = gastrodermis, m = mesoglea, bar = 20 μm for all photos.

Author's personal copy

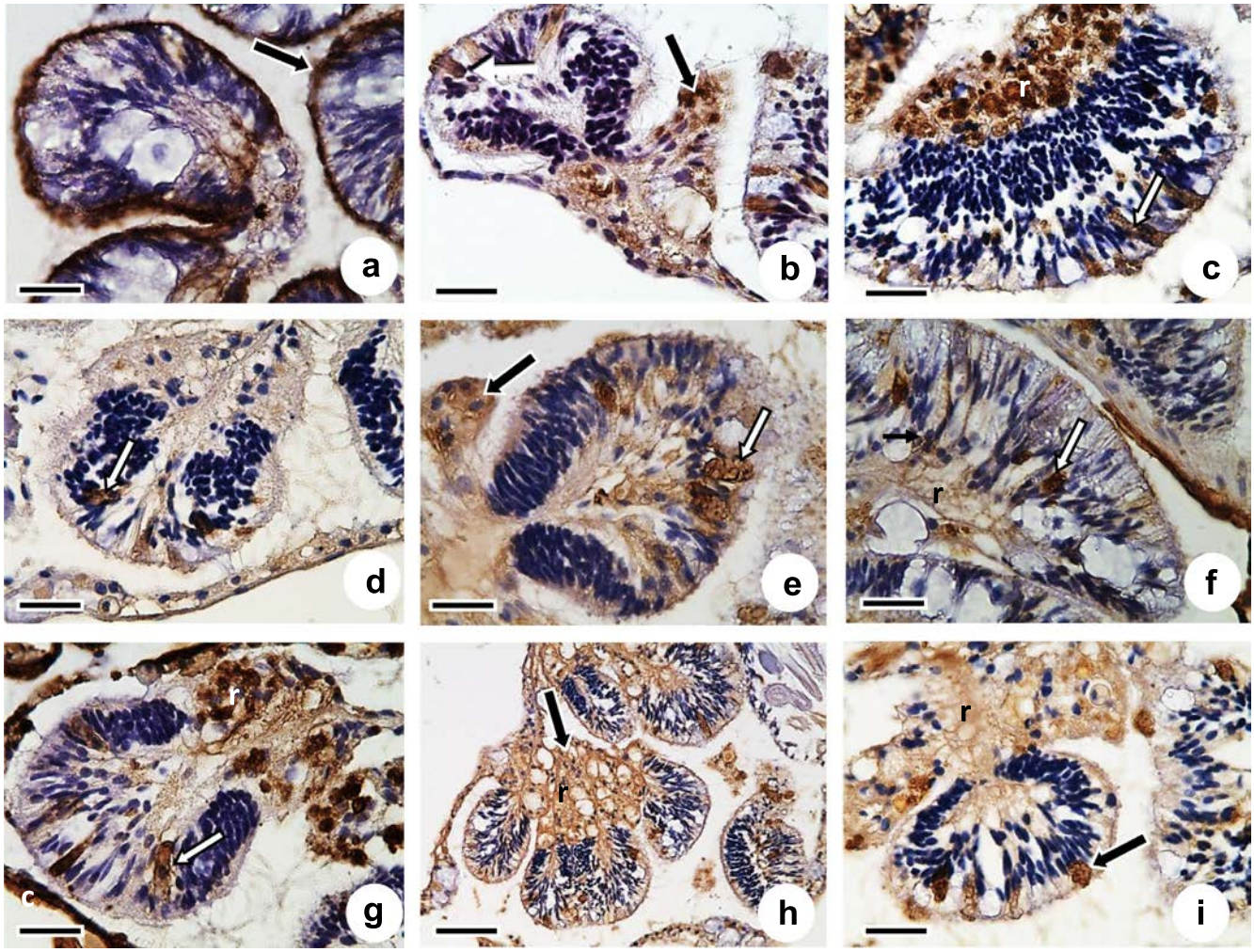

Fig. 3. *Montipora capitata* mesenterial filaments. (a) *Ulex europaeus* (UEA)-note strong staining of superficial portion of cnidoglandular tract (arrow). (b) *Griffonia simplicifolia* I (GSL-1)-note strong staining of granular gland cells (white arrow) in cnidoglandular tract and staining of ciliated and reticular tract (black arrow). (c) *Arachis hypogaea* (PNA)-note staining of spirocysts (white arrow) and dark staining of reticular/ciliated tract. (d) *Saphora japónica* (SJA)-Note brown granular gland cells in cnidoglandular tract (arrow). (e) *Griffonia simplicifolia* II (GSL-II)-note strong staining of granular gland cells (arrow) in cnidoglandular cap and staining of ciliated tract (black arrow). (f) *Lycopersicon esculentum* (LEA)-Note strong staining of deep granular cells (white arrow) and weak staining of reticular/ciliated tract. (g) *Solanum tuberosum* (STL)-note strong staining of granular gland cells in cnidoglandular cap (arrow) and staining of reticular and ciliated tracts. (h) *Phaseolus vulgaris*-E (PHA-E)-note diffuse staining of reticular tract (arrow). (i) *Phaseolus vulgaris*-L (PHA-L)-Note staining of granular gland cells (arrow) in cnidoglandular tract and weak staining of reticular/ciliated tract. c = calicodermis r = reticular/ciliated tract gastrodermis, m = mesoglea, bar = 20 μm for all photos.

included epidermal gland cells, epidermal mucocytes, epidermal basal granules, epidermal apical granules, epidermal apical cytoplasm and cilia, mesoglea, gastrodermis cytoplasm, gastrodermis basal granules, zooxanthellae, calicodermis, spirocyst, mature holotrichous isorhizas, nematoblasts, cnidoglandular tract granular gland cells, cnidoglandular tract cell surface membrane, reticular/ciliary tract, yolk, perivitelline space, perivitelline cell basal granules, perivitelline cell cytoplasm, perivitelline cell basal lamina, sperm, periseminal cell basal lamina, periseminal stroma, periseminal cell basal granules, and periseminal cell cytoplasm (Table 2). For each structure, staining was subjectively graded as absent, weak, or strong. For data presentation, lectins were grouped according to the families of their conjugate sugars including L-fucose, N-acetyl-galactosamine, Sialic acid, Mannose, and N-acetyl-glucosamine (Damjanov, 1987).

Total anatomical structures identified by each lectin were added for upper and basal body wall. Lectin specificity was assessed by quantifying how many structures were stained by a particular lectin. For example, a lectin staining only a single structure was judged to be more specific than one staining multiple structures. Similarly, sugar cross reactivity for each anatomical structure was assessed by tallying the number of lectins by which it was stained. For instance, a structure stained by only a single lectin was deemed to have less cross-reactive sugars than one stained by multiple lectins.

3. Results

Lectins differentially stained specific structures in all tissue compartments including actinopharynx (Fig. 1), coenenchyme (Fig 2), mesenterial filaments (Fig. 3), nematocysts (Fig. 4), ova (Fig. 5) and spermaries (Fig 6). In particular, several structures and cell types were stained with lectins that were not previously evident as distinct entities on hematoxylin and eosin (Table 2). For coenenchyme, these enhanced structures included epidermal apical and gastrodermal basal granules stained with PNA (Fig 1c). For actinopharynx, apical epidermal cytoplasm and ciliae stained with UEA (Fig. 2a) and epidermal and gastrodermal granules stained with PNA (Fig. 2c). For mesenterial filaments,

Author's personal copy

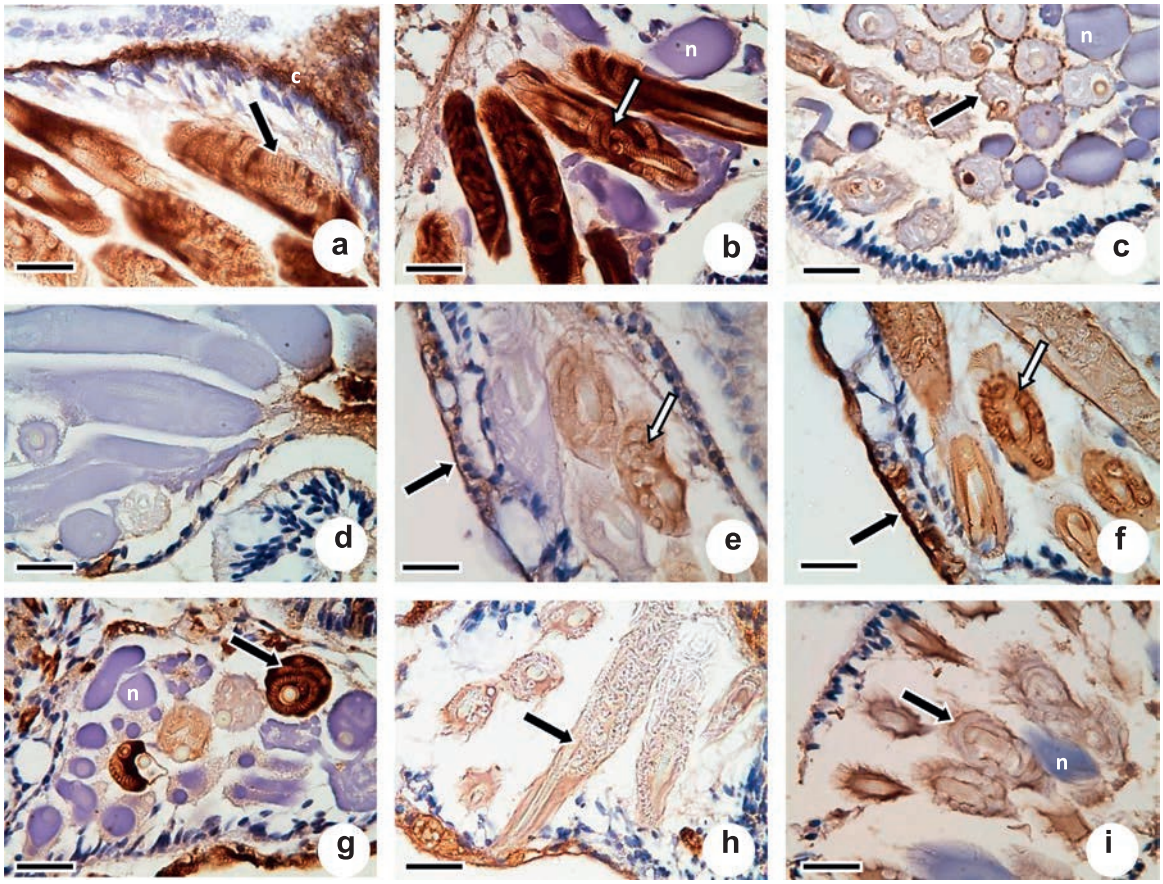

Fig. 4. *Montipora capitata* nematocyst batteries. (a) *Ulex europaeus* (UEA)-Note strong staining of holotrichous isorhizas (arrow) and calicodermis. (b) *Griffonia simplicifolia* I (GSL-1)-note strong staining of holotrichous isorhizas (arrow), mesoglea, and epidermal granular gland cells (white arrow). (c) *Arachis hypogaea* (PNA)-Note staining of capsule of mature holotrichous isorhizas (arrow). (d) *Saphora japónica* (SJA)-Note lack of staining of nematocysts. (e) *Griffonia simplicifolia* II (GSL-II)-Note weak staining of selected holotrichous isorhizas (white arrow) and calicodermis (black arrow). (f) *Lycopersicon esculentum* (LEA)-Note weak staining of holotrichous isorhizas (white arrow) and calicodermis (black arrow. (g) *Solanum tuberosum* (STL)-note strong staining of selected mature holotrichous isorhizas (arrow). (h) *Phaseolus vulgaris*-E (PHA-E)-Note weak staining of mature holotrichous ishorhizas (arrow). (i) *Phaseolus vulgaris*-L (PHA-L)-Note weak staining of mature holotrichous ishorhizas (arrow). n = nematoblast, c = calicodermis, bar = 20 μm for all photos.

cnidoglandular tract cell surface membrane stained with UEA (Fig. 3a) and capsule of mature holotrichous isorhizas stained with PNA (Fig. 4c). For oocytes, perivitelline cells stained with GSL1 (Fig. 5b), basal granules of perivitelline cells stained with LEA (Fig. 5d), whilst basal membrane stained with PHA-L (Fig. 5f) and perivitelline space stained with PHA-E (Fig. 5e). For spermaries, periseminal cells cytoplasm stained with STL (Fig. 6d), whereas basal granules stained with LEA (Fig. 6c), and basal membrane stained with PHA-L (Fig. 6f).

For upper body wall, SJA stained the fewest structures whereas GSL1 stained the most (Table 2). Based on number of structures stained, specificity of lectins from highest to lowest for upper body wall was SJA > GSL2 = LEA = STL = PHAE > UEA > PHAL > PNA > GSL1. For basal body wall, the order was SJA > UEA > PNA = PHAE > PHAL = LEA > GSL1 = STL > GSL2. For the coenenchyme, the most specifically staining structures (those staining with only a single lectin) included epidermal gland cells, epidermal granules, gastrodermis cytoplasm, and gastrodermis basal granules. For the actinopharynx, the most specific structure included spirocysts, epidermal apical granules, epidermal apical cytoplasm and ciliae, and zooxanthellae. For nematocysts, the most specifically staining structure was the capsule of mature holotrichous isorhizas and cnidoglandular tract cell surface membrane. For oocytes, specific staining structure included perivitelline space and perivitelline cell basal granules, basal lamina, and cytoplasm. For spermaries, specific staining structures included sperm and periseminal cell basal lamina and cytoplasm. The percentage of specifically staining structures was similar for upper (8/17 or 47%) versus basal (9/15 or 60%). Percent of specific staining structures was highest for oocytes (80%) followed by actinopharynx (57%), coenenchyme and spermaries (50% each) and mesenterial filaments (40%) (Table 2).

4. Discussion

One of the challenges in interpretation of coral histology is our rudimentary knowledge of the cell types that comprise the animal and the lack of cell-specific markers (Work et al., 2008). In this study, we showed that lectins will target specific cellular and subcellular structures in *M. capitata*. As such, they could prove useful in targeted studies to better understand host physiology. For example, investigators with an interest in reproductive physiology of corals could monitor the lectin chemistry of gonadal development and maturation using lectins that stain specific structures such as PNA for perivitelline or periseminal cell cytoplasm, LEA for perivitelline cell granules, or PHA-L for perivitelline or periseminal cell basal lamina. Likewise, studies of digestive physiology could take advantage of lectins that specifically target the actinopharynx such as PNA for epidermal or gastrodermal cell granules, and UEA for epidermal cytoplasm and ciliae. Lectins such as PNA or UEA may also prove useful to further our understanding of nematocyst physiology and

Author's personal copy

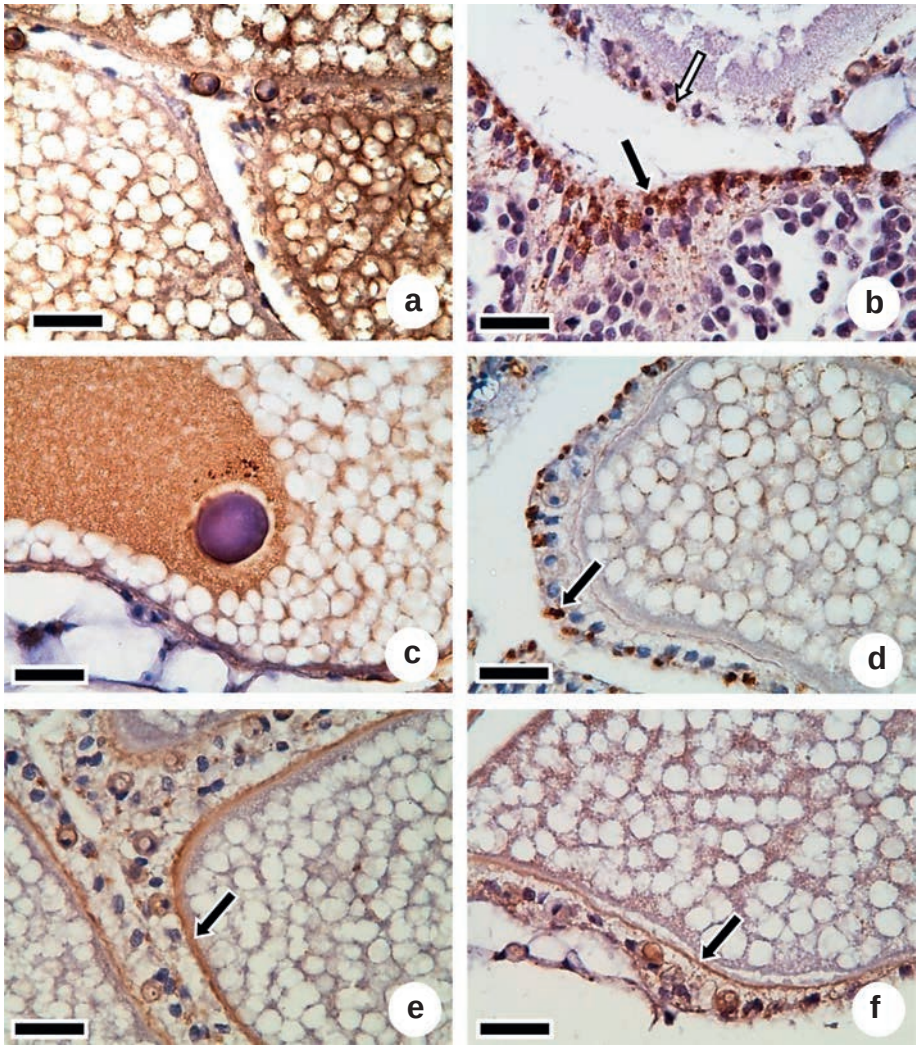

Fig. 5. *Montipora capitata* oocytes. (a) *Griffonia simplicifolia* I (GSL-1)-Note strong staining of yolk. (b) *Arachis hypogaea* (PNA)-Note staining of perivitelline cells (white arrow-top) and periseminal cells (black arrow-bottom). (c) *Griffonia simplicifolia* II (GSL-II)-Note staining of yolk. (d) *Lycopersicon esculentum* (LEA)-Note staining of basal granules (arrow) of perivitelline cells. (e) *Phaseolus vulgaris*-E (PHA-E)-Note staining of perivetelline space (arrow). (f) *Phaseolus vulgaris*-L (PHA-L)-Note staining of basal membrane of perivetelline cells (arrow) and weak staining of zooxanthellae. Bar = 20 μm for all photos.

development. Simultaneous staining of coral tissues with multiple lectins and different colored fluorescent reporters could also confirm whether particular cells stained using methods used here are indeed the same cell type. For example, epidermal granular gland cells are stained with multiple lectins in the actinopharynx, but perhaps these lectins target different types of granular gland cells. If a reliable method were found to disaggregate coral cells into single cell suspensions, lectins could be used to capture certain cell types on affinity columns as performed on other animals (Reisner et al., 1978). For example, SJA could capture exclusively granular gland cells whereas UEA could capture cnidoglandular band or actinopharynx epithelium. Finally, lectin histochemistry of coral ontogeny and abnormal versus normal corals could shed further light on cellular pathophysiology of coral disease as performed, for example, to elucidate tumor biology in mammals (Damjanov, 1987).

Lectin histochemistry has a long history (Damjanov, 1987) and has been used to study anatomy, physiology, and disease pathogenesis in vertebrates and invertebrates. Examples include studies of kidney tubule architecture in humans (Truong et al., 1988), glycobiology of frog skin (Kaltenbach et al., 2004), spermatogenesis in crickets (Suzuki and Nishimura, 1997), immune cells in oysters (Pipe, 1990), and host response of clams to parasites (Montes et al., 1995). However, in corals, lectin studies have typically been limited to evaluating their role in biology of zooxanthellae (Jimbo et al., 2010), their role in bleaching (Vidal-Dupiol et al., 2009), or characterizing lectins from the corals themselves (Kvennefors et al., 2008). To our knowledge, this is the first study to use plant lectins to target cell types in corals. Indeed, the use of biotinylated endogenous lectins from corals (Kvennefors et al., 2008) could be a valuable supplement to the lectins used here to understand cellular physiology of corals.

Thirteen lectins were not found to be useful in this study as all gave excessive background noise that made interpretation of cell types difficult, even at very low concentrations (1 μg/ml) or gave results that could not be reliably replicated (Table 1). We caution, however, that this study only examined one species of coral, and it remains to be determined whether the lectin staining patterns seen here have commonalities with staining patterns in other species of *Montipora* or other genera of corals. Furthermore, we only used a small subset of available plant (Danguy and Gabius, 1993) and animal lectins (Gabius, 2001), and these along with

Author's personal copy

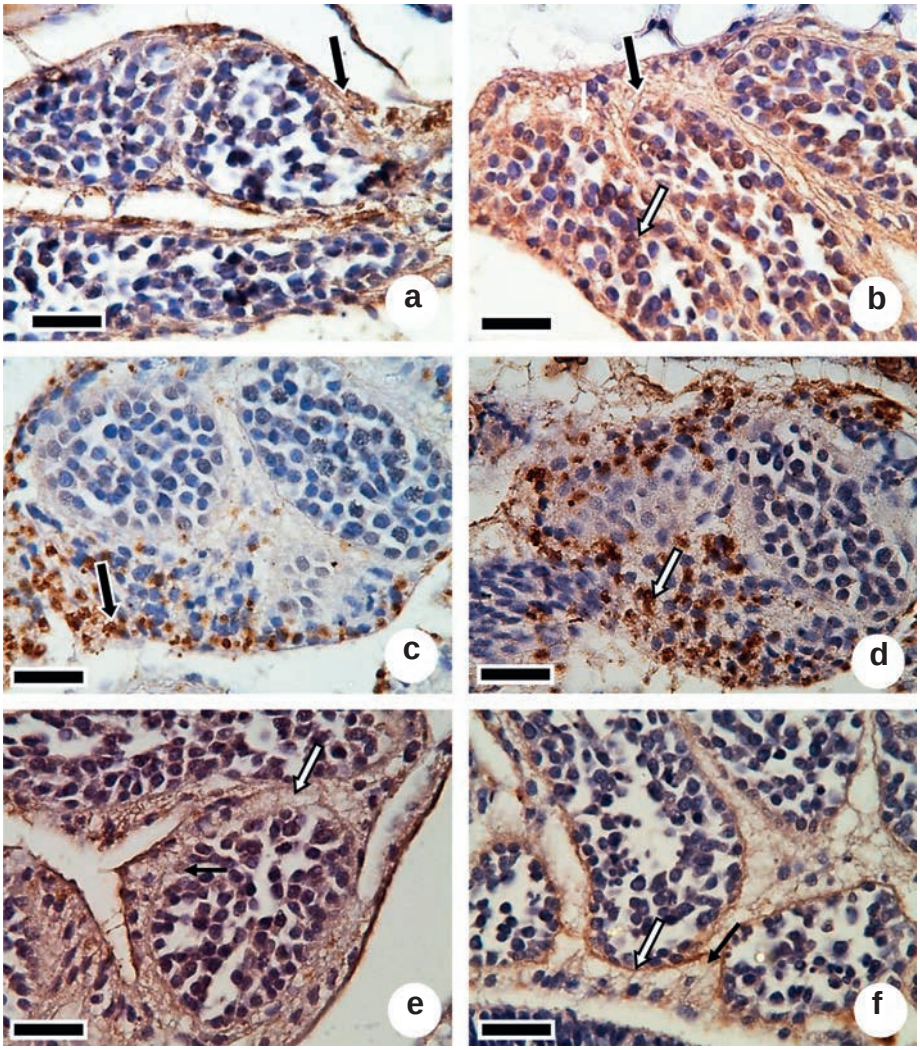

Fig. 6. *Montipora capitata* spermaries. (a) *Griffonia simplicifolia* I (GSL-1)-Note staining of periseminal stroma (arrow). (b) *Griffonia simplicifolia* II (GSL-II)-Note staining of periseminal stroma (black arrow) and selected perm (white arrow). (c) *Lycopersicon esculentum* (LEA)-Note staining of granules (arrow) within periseminal cells (arrow). (d) *Solanum tuberosum* (STL)-Note staining of periseminal cells (arrow). (e) *Phaseolus vulgaris*-E (PHA-E)-Note diffuse staining of periseminal stroma (arrow). (f) *Phaseolus vulgaris*-L (PHA-L)-Note staining of periseminal basal membrane (arrow). Bar = 20 μm for all photos.

endogenous coral lectins (Kvennefors et al., 2008) could be powerful tools to look at the cell biology of corals.

Acknowledgments

Mention of products or trades names does not imply endorsement by the US Government. We thank Julie Dagenais for technical assistance. Val Bochsler provided constructive comments on this manuscript.

References

Brooks, S.A. et al., 1996. Lectin Histochemistry: A Concise Practical Handbook. BIOS Scientific, Herndon, Virginia.
Cheville, N.F., 1988. Introduction to Veterinary Pathology. Iowa State University Press, Ames.
Damjanov, I., 1987. Biology of disease lectin cytochemistry and histochemistry. Lab. Invest. 57, 1–16.
Danguy, A., Gabius, H.J., 1993. Lectins and neoglycoproteins: attractive molecules to study glycoconjugates and accessible sugar-bin. In: Gabius, H.J., Gabius, S. (Eds.), Lectins and Glycobiology. Springer-Verlag, Berlin, pp. 241–250.
Fautin, D.G., Mariscal, R.N., 1991. Cnidaria: Anthozoa. Wiley-Liss, New York.
Gabius, H.J., 2001. Glycohistochemistry: The why and how of detection and localization of endogenous lectins. Anat. Histol. Embryol. 30, 3–31.
Galloway, S.B., et al., 2006. Coral Disease and Health Workshop: Coral Histopathology II. National Oceanic and Atmospheric Administration, Silver Springs.
Green, E.P., Bruckner, A.W., 2000. The significance of coral disease epizootiology for coral reef conservation. Biol. Conserv. 96, 347–361.
Hoegh-Guldberg, O., 1999. Climate change, coral bleaching and the future of the world's coral reefs. Mar. Freshw. Res. 50, 839–866.
Hyman, L.H., 1940. The Invertebrates: Protozoa through Ctenophora. McGraw-Hill, New York.
Jimbo, M. et al., 2010. Effects of lectin in the scleractinian coral ctenactis echinata on symbiotic zooxanthellae. Fish. Sci. 76, 355–363.
Kaltenbach, J.C. et al., 2004. Glycoconjugate localization in larval and adult skin of the bullfrog, *Rana catesbeiana*: a lectin histochemical study. J. Morphol. 261, 184–195.
Kopecky, E.J., Ostrander, G.K., 1999. Isolation and primary culture of viable multicellular endothelial isolates from hard corals. In Vitro Cell Dev. Biol. – Anim. 35, 616–624.
Kvennefors, E.C.E. et al., 2008. An ancient and variable mannose-binding lectin from the coral *Acropora millepora* binds both pathogens and symbionts. Dev. Comp. Immunol. 32, 1582–1592.
Montes, J.F. et al., 1995. Cellular defence mechanism of the clam Tapes semidecussatus against infection by the protozoan *Perkinsus* sp.. Cell Tissue Res. 279, 529–538.
Pipe, R.K., 1990. Differential binding of lectins to haemocytes of the mussel *Mytilus edulis*. Cell Tissue Res. 261, 261–268.
Reisner, Y. et al., 1978. Hemopoietic stem cell transplantation using mouse bone marrow and spleen cells fractionated by lectins. Proc. Nat. Acad. Sci. 75, 2933–2936.

Author's personal copy

Sutherland, K.P. et al., 2003. Disease and immunity in Caribbean and Indo-Pacific zooxanthellate corals. Mar. Ecol. Prog. Ser. 266, 273–302.
Suzuki, A.C., Nishimura, K., 1997. Glycoconjugate profiles of insect spermatogenesis: lectin cytochemical analysis of the cricket, *Gryllus bimaculatus*. Zool. Sci. 14, 455–467.
Truong, L.D. et al., 1988. Glycoconjugates in normal human kidney. Histochem. Cell Biol. 90, 51–60.
Vidal-Dupiol, J. et al., 2009. Coral bleaching under thermal stress: putative involvement of host/symbiont recognition mechanisms. BMC Physiol. 9, 14.
Waddell, J.E., Clarke, A.M., 2008. The State of Coral Reef Ecosystems of the United States and Pacific Freely Associated States. NOAA Technical Memorandum NOS NCCOS 73. NOAA, Silver Springs, MD, 2008, pp. 569.
Willis, B.L. et al., 2004. Coral disease on the Great Barrier Reef. In: Loya, Y., Rosenberg, E. (Eds.), Coral Health and Disease. Springer, Heidelberg, pp. 69–104.
Work, T.M. et al., 2008. Biomedical and veterinary science can increase our understanding of coral disease. J. Exp. Mar. Biol. Ecol. 362, 63–70.
Work, T.M. et al., 2012. Tissue loss (white syndrome) in the coral *Montipora capitata* is a dynamic disease with multiple host responses and potential causes. Proc. Roy. Soc. B 279, 4334–4341.