Journal of Invertebrate Pathology 120 (2014) 50–58

Contents lists available at ScienceDirect

Journal of Invertebrate Pathology

journal homepage: www.elsevier.com/locate/jip

Gross and microscopic pathology of hard and soft corals in New Caledonia

Thierry M. Work [a,*], Greta S. Aeby [b], Gregory Lasne [c], Aline Tribollet [d]

[a] U.S. Geological Survey, National Wildlife Health Center, Honolulu Field Station, PO Box 50187, Honolulu, HI 96850, USA
[b] Hawaii Institute of Marine Biology, PO Box 1346, Kaneohe, HI 96744, USA
[c] BIOCENOSE MARINE Sarl, Centre IRD de Nouméa, 98848 Nouméa Cedex, New Caledonia
[d] UMR IPSL-LOCEAN (UPMC/CNRS/IRD/MNHN), Centre IRD France Nord, 32 Av. Henri Varagnat, 93143 Bondy Cedex, France

ARTICLE INFO

Article history:
Received 29 November 2013
Accepted 27 May 2014
Available online 10 June 2014

Keywords:
Histopathology
Coral
Disease
New Caledonia
Endolithic hypermycosis
Porites trematodiasis

ABSTRACT

We surveyed the reefs of Grande Terre, New Caledonia, for coral diseases in 2010 and 2013. Lesions encountered in hard and soft corals were systematically described at the gross and microscopic level. We sampled paired and normal tissues from 101 and 65 colonies in 2010 and 2013, respectively, comprising 51 species of corals from 27 genera. Tissue loss was the most common gross lesion sampled (40%) followed by discoloration (28%), growth anomalies (13%), bleaching (10%), and flatworm infestation (1%). When grouped by gross lesions, the diversity of microscopic lesions as measured by Shannon–Wiener index was highest for tissue loss, followed by discoloration, bleaching, and growth anomaly. Our findings document an extension of the range of certain diseases such as *Porites* trematodiasis and endolithic hypermycosis (dark spots) to the Western Pacific as well as the presence of a putative cnidarian endosymbiont. We also expand the range of species infected by cell-associated microbial aggregates, and confirm the trend that these aggregates predominate in dominant genera of corals in the Indo-Pacific. This study highlights the importance of including histopathology as an integral component of baseline coral disease surveys, because a given gross lesion might be associated with multiple potential causative agents.

Published by Elsevier Inc.

1. Introduction

The Pacific Ocean harbors the vast majority of coral biodiversity in the world; however, these ecosystems face significant threats including global climate change (Hoegh-Guldberg et al., 2007; Pandolfi et al., 2011), land-based sources of pollution (Fabricius, 2005), overfishing (Jackson, 2008), and disease (Harvell et al., 2004). The latter has been responsible for declines of 80% of coral cover in the Caribbean over the past two decades (Gardner et al., 2003). Many causes of coral diseases are unknown, because relatively little attention is paid to examining coral tissues at the light microscope level, and most efforts focus on microbial cultures or molecular biology (Bourne et al., 2009; Work and Meteyer, 2014). This is unfortunate because microscopic examination of coral tissues can help visualize agents associated with lesions in corals as well as host response to these agents (Work et al., 2012). Understanding what is occurring at the tissue level can also help in designing laboratory tests, and provides a morphological baseline for use in experimental trials to confirm causation of lesions (Work and Meteyer, 2014; Work et al., 2008c).

Diseases in wildlife are interplays between agent(s) (the cause of disease), hosts (animal affected), and the environment where they interact. Corals are a unique case in wildlife disease ecology, because the corals as main frame builders of tropical reef ecosystems are, essentially, the environment. In tropical oceans, coral reefs provide fundamental ecosystem services that underpin tropical marine diversity and generate socio-economic values including income from fisheries, tourism, ocean technologies, and coastal protection (Moberg, 1999). For example, in Hawaii alone, coral reefs are estimated to contribute ca. $US 10 billion (2004 dollars) annually to the economy (Cesar and van Beukering, 2004). Degradation of corals has myriad adverse effects including loss of three dimensional structure of the substrate, associated fish, invertebrates, and other animals that depend on corals for food and shelter (Paulay, 1996). It is all the more critical, then, to obtain baseline information on potential causes of coral lesions in sensitive habitats before catastrophic disease outbreaks occur.

* Corresponding author. Address: USGS, PO Box 50167, Honolulu, HI 96850, USA. Fax: +1 808 792 9596.
E-mail address: Thierry_work@usgs.gov (T.M. Work).

http://dx.doi.org/10.1016/j.jip.2014.05.007
0022-2011/Published by Elsevier Inc.

One such habitat is the lagoon of New Caledonia, the largest in the world harboring one of the most diverse communities of marine fauna and flora (Roberts et al., 2002). About 60% of the Caledonian reefs were designated as a UNESCO World Heritage Site in 2008. Due to rapid urban and industrial development (the New Caledonian nickel industry is the 3rd largest one in the world), nearshore coral reefs in this region are exposed to anthropogenic inputs (Fernandez et al., 2006) and natural terrestrial run off (Fichez et al., 2010) that in concert with global climate change could adversely affect coral reef health. To get a better sense of coral reef health in the region, we did for the first time baseline coral disease surveys in 14 sites comprising seven inshore reefs, six barrier reefs, and one lagoonal patch reef surrounding the largest island of New Caledonia (Grande Terre) in summers of 2010 and 2013. Our objectives were to systematically describe coral lesions encountered during surveys in the region at the gross and microscopic level.

2. Methods

2.1. Sampling and gross pathology

We sampled coral colonies from 14 and 12 sites around New Caledonia in January–February 2010 and 2013, respectively (Fig. 1) according to the protocol by Work and Aeby (2006). For *in situ* characterization of gross lesions, entire colony and lesions were photographed and the following data were recorded: date, location (GPS coordinates), and depth of collection. Grossly, lesions were classified into three broad categories including tissue loss, discoloration, and growth anomaly. Tissue loss was subdivided as acute, subacute, subacute with band characterized by healthy tissue separated from bare skeleton by a colored band, or chronic (Raymundo et al., 2008; Work and Aeby, 2006). Discoloration was categorized as bleaching (white discoloration subdivided as localized, multifocal, or diffuse), dark discoloration comprising variably sized distinct irregular dark brown areas, multifocal pink-to-pale discoloration comprising numerous 2–4 mm pink-to-pale spots, and other discoloration (all other categories). Growth anomalies were categorized as umbonate, exophytic, rugose, or nodular (Work et al., 2008a).

For histopathology, coral fragments (2–5 g) were collected with chisel or bone shears and placed into individually numbered whirlpak bags in seawater. Fragments with lesions were collected ensuring that the border between normal and lesion tissues was incorporated. When available, paired apparently normal fragments were also collected. Coral fragments were processed for histopathology as described (Work and Aeby, 2011). Briefly, fragments were fixed in Z-Fix (Anatech Ltd.) diluted 1:5 with seawater, decalcified in dilute formic acid/formaldehyde solution (Cal-Ex II, Fisher Scientific), tissues dehydrated in alcohol, embedded in paraffin, sectioned at 5 μm, and stained with hematoxylin and eosin.

2.2. Histopathology and data analyses

Microscopic changes were interpreted in light of findings from paired normal fragments and broadly categorized by agent associated with cell pathology, if present, and host response. Agents were identified according to their microscopic morphology and included sponges or cnidaria (Hyman, 1940a), helminths (Hyman, 1940b), ciliates (Bourne et al., 2008), algae (McCook et al., 2001), fungi (Larone, 1976), cyanobacteria (Stanier and Cohen-Bazire, 1977), and molluscs or crustacea (Ruppert et al.,

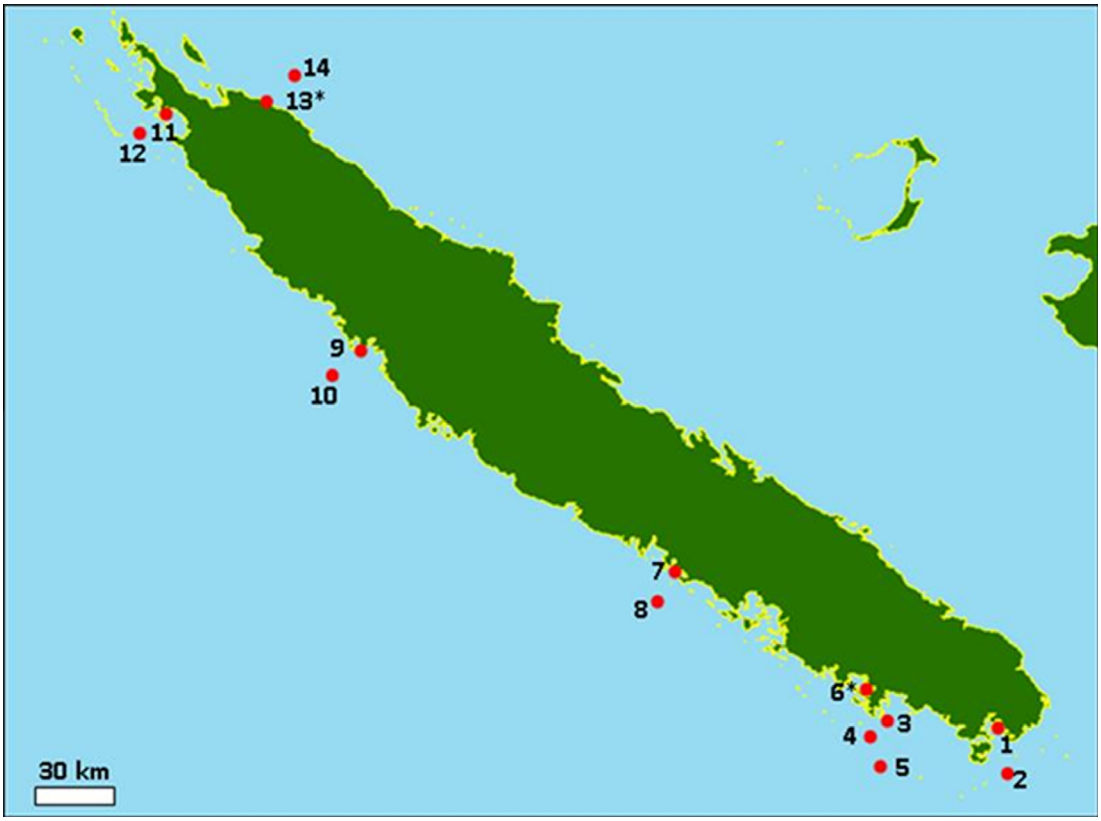

Fig. 1. Collection sites for coral lesions in 2010 and 2013 around the largest island of New Caledonia, Grande Terre. 1 – Ilôt Casy (inshore fringing reef), 2 – Gué reef (barrier reef), 3 – Baie des Citrons (inshore fringing reef), 4 – Sèche Croissant reef (lagoonal patch reef), 5 – Mbere reef (barrier reef), 6 – Banc des Japonais* (inshore reef), 7 – Chenal de Teremba (inshore reef), 8 – Passe de Ouaraï (barrier reef), 9 – Kreliat reef (inshore reef), 10 – Passe de Koné (barrier reef), 11 – Bouerabate reef (inshore reef), 12 – Passe de la Gazelle (barrier reef), 13 – Neongaon reef* (inshore reef), 14 – Balade reef (barrier reef in front of the Col d'Amos). Sites with asterisks (*) were surveyed in 2010 only.

2004). Sulfur granule-containing bacteria were differentiated from larger cyanobacteria based on morphology, size and presence of characteristic granules on phase contrast microscopy (Larkin and Strohl, 1983; Miller et al., 2011). Host response or changes broadly followed those outlined elsewhere (Work et al., 2012) and included tissue fragmentation, suspect wound repair, hyperplasia of basal body wall, necrosis, and inflammation (infiltration of mesogleal cells at or near site of cell pathology or agent). Microscopic changes were not mutually exclusive, and in such cases, the most severe change took priority when assigning categories. Thus, if an agent was associated with a lesion, it took priority (primary agent), and if no agent was seen but host response was present, host response took priority (primary host response). Finally, presence of cell-associated microbial aggregates in tissues was documented (Work and Aeby, 2014).

We used the Shannon–Weiner diversity index to examine diversity of microscopic lesions associated with broad categories of gross lesions including bleaching, discoloration, tissue loss, and growth anomaly (Shannon, 1948).

3. Results

3.1. Gross lesions

We sampled a total of 101 and 65 colonies in 2010 and 2013, respectively. Of 166 colonies sampled, 11% each came from Pointe Bouerabate or Baie des Citrons, 10% came from Gué, 9% from the Récif de la Balade (Col d'Amos), 8% each from Mbéré or Chenal de Téremba, 7% each from Ilôt Casy, Kréliat reef, Passe de Koné, or Passe de La Gazelle, 5% each from Banc des Japonais or Neongaon, 4% from Ouaraï, and the remainder from Sèche Croissant. The 166 colonies comprised 52 species of corals among 28 genera with *Acropora*, *Porites*, and *Montipora* dominating (Table 1).

Of all lesion categories sampled, 40% were tissue loss followed by 28% discoloration, 13% growth anomaly, 10% bleaching, and 1% flatworm infestation. For tissue loss, 55% were acute (Fig. 2a) followed by 39% subacute (Fig. 2b), and 3% each subacute with band (Fig. 2c) and chronic (Fig. 2d). For discoloration, 57% were multifocal (Fig. 2e), 28% were "Other" (Fig. 2f), and 15% were dark discoloration (Fig. 2g). Sixty-one percent of bleached lesions were diffuse (Fig. 2h) followed by 29% multifocal (Fig. 2i) and 10% localized (Fig. 2j). Thirty-six percent of growth anomalies were nodular (Fig. 2k), 32% umbonate, (Fig. 2l), 18% rugose (Fig. 2m), and 14% exophytic (Fig. 2n). Only a single flatworm infestation (Fig. 2o) was seen. *Porites* were over represented for multifocal discoloration whereas *Montipora* and *Acropora* were dominant genera for tissue loss (Table 2).

Table 1
Percent (n) of 166 colonies of corals sampled for histology from New Caledonia in 2010 and 2013 partitioned by species.

Species	% (n)	Species	% (n)
Acanthastrea hemprichii	1 (1)	*Merulina scabricula*	1 (2)
Acropora austera	5 (8)	*Millepora foveolata*	1 (1)
Acropora florida	2 (3)	*Montastrea* sp.	1 (1)
Acropora formosa	1 (1)	*Montipora aequituberculata*	1 (2)
Acropora kyrstiae	1 (1)	*Montipora digitata*	3 (5)
Acropora mirabilis	1 (1)	*Montipora foliosa*	1 (1)
Acropora muricata	5 (8)	*Montipora malampaya*	1 (1)
Acropora paniculata	1 (1)	*Montipora millepora*	1 (2)
Acropora seriata	1 (1)	*Montipora* sp.	5 (9)
Acropora sp.	7 (11)	*Pachyseris speciosa*	1 (2)
Acropora yongei	2 (3)	*Pavona varians*	2 (4)
Astreopora listeri	1 (1)	*Pectinia lactuca*	1 (2)
Astreopora myriophthalma	3 (5)	*Platygyra daedalea*	1 (1)
Coscinaraea columna	1 (1)	*Pocillopora damicornis*	1 (1)
Echinopora sp.	1 (1)	*Pocillopora meandrina*	1 (1)
Favia sp.	2 (4)	*Pocillopora* sp.	1 (1)
Favia truncatus	1 (1)	*Pocillopora verrucosa*	1 (1)
Favites pentagona	1 (1)	*Porites annae*	1 (1)
Favites sp.	2 (4)	*Porites* sp.	30 (50)
Favites stylifera	1 (1)	*Sinularia* sp.	4 (6)
Fungia concinna	1 (2)	*Stylophora pistillata*	1 (1)
Galaxea paucisepta	1 (1)	*Symphyllia recta*	1 (1)
Goniastrea sp.	1 (1)	*Symphyllia wilsoni*	1 (1)
Isopora palifera	1 (1)	*Turbinaria mesenterina*	1 (1)
Leptoria phrygia	1 (2)	*Turbinaria retiformis*	1 (2)
Lobophytum sp.	1 (1)		

3.2. Agents associated with lesions

For bleached corals, the most common microscopic lesion found was depletion of zooxanthellae from upper and basal body wall (45%) followed by fungal infection (10%), algae, fragmentation of tissues, or inflammation (3% each) with the remainder showing no microscopic lesions.

For discoloration, 20% had algal invasion at the microscopic level followed by fungi or inflammation (17% each), helminths (7%), mucus hyperplasia or necrosis (4% each), cyanobacteria, fragmentation, or hyperplasia of basal body wall (2% each) with the remainder manifesting no lesions. For multifocal pink-to-pale discoloration, 35% and 31%, respectively had algae or inflammation as primary histologic finding followed by helminths, necrosis, or cyanobacteria. Most (71%) of dark discoloration lesions were associated with fungal infection with the remainder manifesting mucus hyperplasia. Sixty-nine percent of "Other" discoloration had no evident microscopic lesions.

The majority of growth anomalies (38–75%), regardless of morphology, had microscopic evidence of hyperplasia of basal body wall with a minority of cases having crustacea or inflammation.

Finally, for acute and subacute tissue loss, no one type of microscopic finding predominated; however, half of chronic tissue loss cases had fungi, and all subacute tissue loss with banding had evidence of cyanobacterial infections. When broad diagnostic categories were examined for diversity of microscopic lesions using the Shannon-Wiener index, tissue loss had the highest diversity ($H = 2.23$, $n = 66$) followed by discoloration ($H = 1.63$, $n = 46$), bleaching ($H = 1.27$, $n = 31$) and growth anomaly ($H = 1.11$, $n = 22$).

3.3. Host response

In cases of a primary agent as the microscopic diagnosis, we recorded host responses that varied depending on the agent. Twenty percent of 20 fungal infections were associated with fragmentation, 15% with necrosis and 5% with inflammation (Fig. 3a). Of 18 algal diagnoses, 50% were associated with necrosis, 28% with fragmentation, and 22% with inflammation (Fig. 3b). Forty-five percent of 11 helminth infections were associated with necrosis with 27% having fragmentation (Fig. 3d) and 9% inflammation. Trematodes were identified in three of the helminth infections and characterized by presence of characteristic acetabulum (Fig. 3d). All of six ciliate infections were associated with necrosis, and in these lesions, ciliates did not necessarily always contain zooxanthellae (Fig. 3e). Of four cyanobacterial infections, half were associated with necrosis and a quarter each with fragmentation or inflammation. In one of these, cyanobacterial infections seen in a *Porites* sp. manifesting multifocal pale-to-pink discoloration, the cyanobacteria were mixed with sulfur granule-containing bacteria (Fig. 3f). All mollusc infestations were associated with fragmentation, whereas all sponge infestations were associated with necrosis.

In cases where host response was the primary diagnosis, associated secondary response varied with the lesion. For 16 primary diagnoses of depletion of zooxanthellae, 13% had associated tissue atrophy. For 9 primary fragmentation diagnoses, 22% had associated suspect wound repair (Fig. 3g) and 11% had associated necrosis. For 8 primary wound repair diagnoses, 13% had associated inflammation.

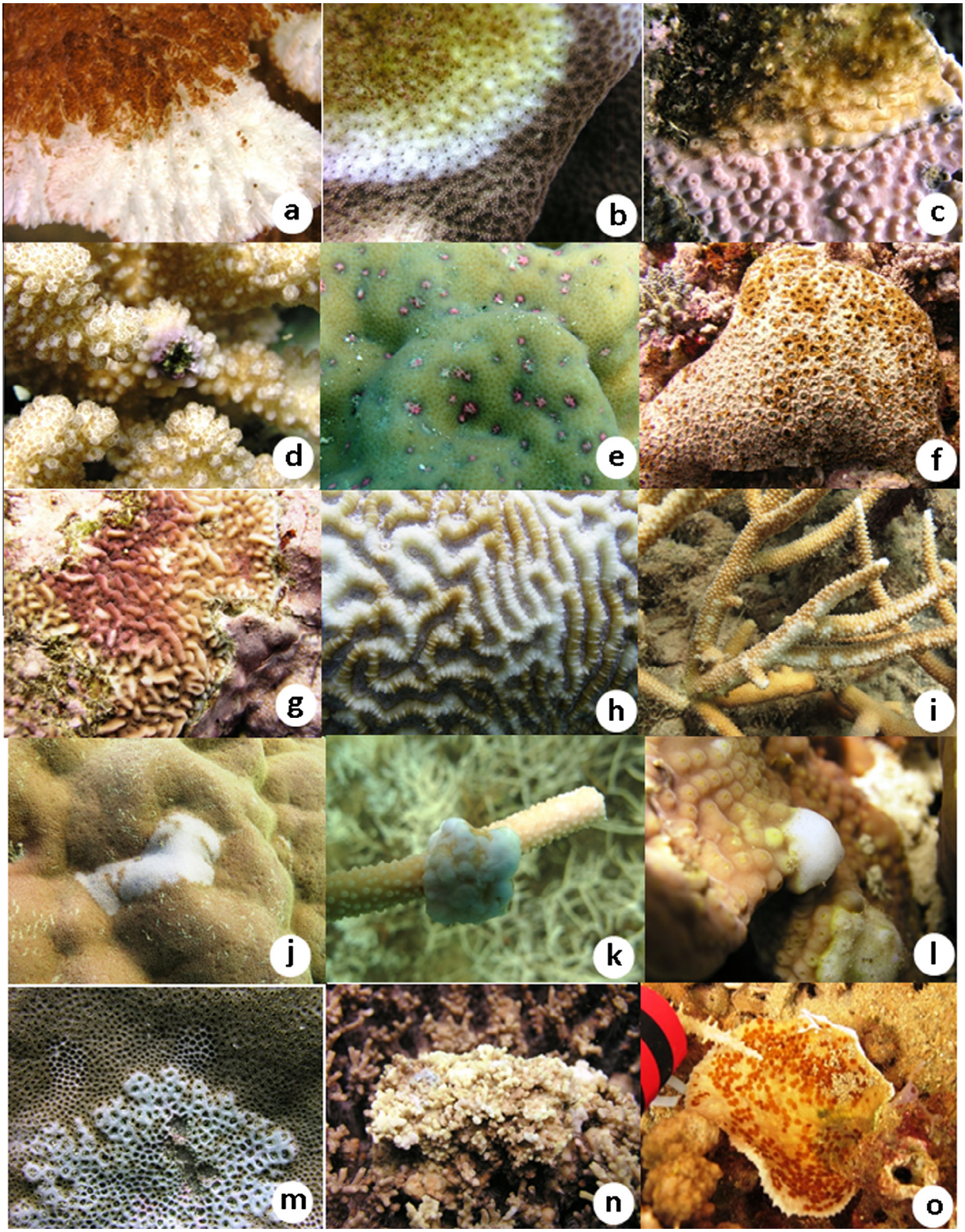

Fig. 2. Gross lesion encountered in corals from New Caledonia in 2010 (a–f; l–m) and 2013 (g–k, n–o). (a) Acute tissue loss in *Merulina scabricula* from Banc des Japonais. (b) Subacute tissue loss in *Coscinaraea columna* from Mbéré reef. (c) Subacute tissue loss with bands in *Turbinaria mesenterina* from Neongaon reef. (d) Chronic tissue loss in *Pocillopora verrucosa* from Gué reef. (e) Multifocal discoloration in *Porites* sp. from Neongaon reef. (f) Other discoloration in *Favia* sp. from Passe de Ouaraï. (g) Dark discoloration in *Pavona varians* from Passe de Koné. (h) Diffuse bleaching in *Platygyra daedalea* from Kréliat reef. (i) Multifocal bleaching in *Acropora muricata* from Baie des Citrons. (j) Localized bleaching in *Porites* sp. from Chenal de Téremba. (k) Nodular growth anomaly in *Acropora austera* from fringing reef Ilôt Casy. (l) Umbonate growth anomaly in *Turbinaria retiformis* from Gué reef. (m) Rugose growth anomaly in *Porites* sp. from Passe de la Gazelle. (n) Exophytic growth anomaly in *Acropora* sp. from Passe de Koné. (o) Flatworm infestation in *Pectinia lactuca* from fringing reef Ilôt Casy.

Table 2
Percent (*n*) of gross lesions seen in various coral genera in 166 colonies collected from New Caledonia in 2010 and 2013.

Genus	Bleaching			Discoloration			Growth anomaly				Tissue loss				Flatworm	Total
	Diffuse	Multifocal	Focal	Multifocal	Other	Dark	Nodular	Exophytic	Rugose	Umbonate	Acute	Subacute	Chronic	Subacute band		
Acanthastrea					100 (1)											1
Acropora	8 (3)	5 (2)					3 (1)	5 (2)			42 (16)	37 (14)				38
Astreopora	17 (1)			17 (1)	17 (1)				17 (1)		17 (1)	17 (1)				6
Coscinaraea												100 (1)				1
Echinopora	100 (1)															1
Favia	40 (2)				40 (2)	20 (1)										5
Favites	33 (2)				33 (2)	33 (2)										6
Fungia	100 (2)															2
Galaxea	100 (1)															1
Goniastrea	100 (1)															1
Isopora										100 (1)						1
Leptoria		50 (1)				50 (1)										2
Lobophytum	100 (1)															1
Merulina											100 (2)					2
Millepora		100 (1)														1
Montastrea											100 (1)					1
Montipora		5 (1)			10 (2)		10 (2)			5 (1)	50 (10)	15 (3)		5 (1)		20
Pachyseris											50 (1)	50 (1)				2
Pavona						75 (3)						25 (1)				4
Pectinia											50 (1)				50 (1)	2
Platygyra	100 (1)															1
Pocillopora											50 (2)		50 (2)			4
Porites	8 (4)	8 (4)	6 (3)	49 (25)	6 (3)		4 (2)		6 (3)	8 (4)		6 (3)				51
Sinularia					33 (2)		50 (3)					17 (1)				6
Stylophora											100 (1)					1
Symphyllia										50 (1)		50 (1)				2
Turbinaria										33 (1)	33 (1)			33 (1)		3

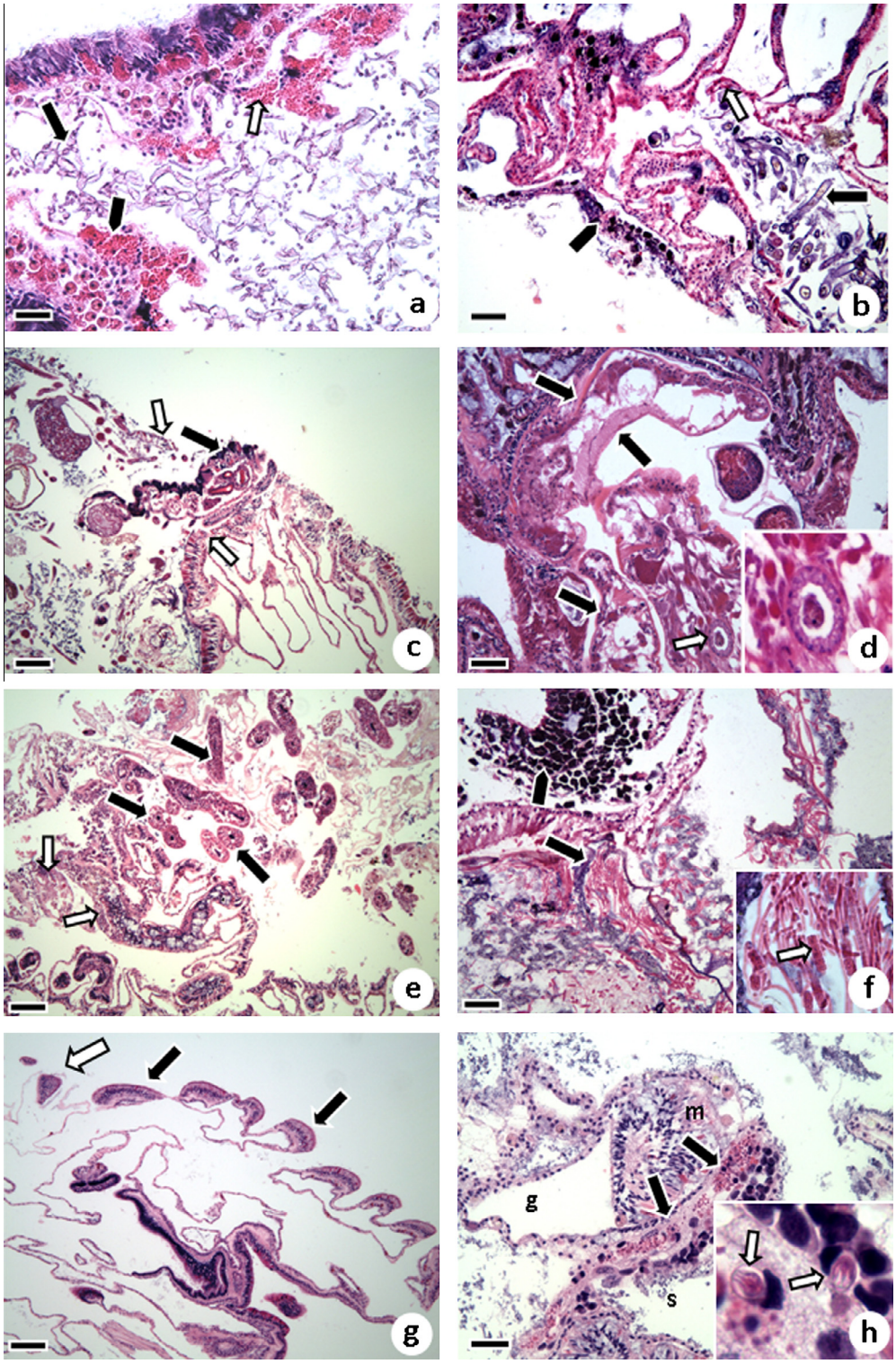

Fig. 3. Photomicrographs of most commonly encountered organisms associated with gross lesions in corals. (a) *Pocillopora verrucosa* with chronic tissue loss, Gué, 2010; note mats of fungal hyphae invading superficial skeleton (black arrow) associated with fragmented tissues (white arrow) and infiltrates of eosinophilic granular cells (arrowhead). Epidermis is on upper left; bar = 20 μm. (b) Massive *Porites* sp. with multifocal discoloration from Passe de Koné, 2013; note algae (black arrow) associated with necrotic debris (white arrow) and marked infiltrates of granular brown cells (black arrowhead) within adjoining atrophied epidermis; bar = 50 μm. (c) *Acropora austera* from Passe de Koné with subacute tissue loss; note helminth (black arrow) invading intact tissue with associated fragmentation (white arrows); bar = 100 μm. (d) *Porites* sp. with multifocal discoloration from Chenal de Téremba, 2013; note presence of helminth delineated with black arrows and acetabulum (white arrow) indicating this to be trematode; bar = 50 μm. Inset-close up of acetabulum. (e) *Acropora muricata* from Bouerabate reef with acute diffuse tissue loss; note large amounts of ciliates (black arrow) effacing basal body wall associated with necrotic debris (white arrow); bar = 100 μm. (f) *Porites* sp. from Chenal de Téremba, 2013 with multifocal discoloration; note clumps of cyanobacteria (black arrow) effacing basal body wall and marked infiltrates of granular brown cells (arrowhead); bar = 50 μm. Inset-close up of larger cyanobacteria trichrome (white arrow) among smaller sulfur-granule containing bacteria. (g) *Acropora florida* with acute tissue loss from Balade reef in 2010; note localized areas of ablated upper body wall (white arrow) with segmental regeneration of epidermis (black arrow); bar = 100 μm. (h) Vermiform metazoan (black arrow) in skeleton (s) adjacent to mesenterial filament (m) within gastrovascular canals (g); bar = 10 μm. Inset are cnidocytes (arrow) with eccentric nuclei within microcnidarian that are ca. 5 μm diameter.

Microscopic cnidiaria characterized by vermiform multicellular structures with distinct cnidae and cnidoblasts (Fig. 3h) were seen in skeleton or mesoglea of basal body wall with no to mild host response (mild deposition of hyaline membranes) in four massive *Porites* and one each *Acropora* sp., *Acropora muricata* and *Acropora austere* from four sites in the south and north of the island. These organisms were seen incidentally in normal and lesioned tissues and were not associated with evident cell pathology.

Of 113 paired normal tissues, 28% had some sort of microscopic lesion with seven manifesting fragmentation, five inflammation, four necrosis or fungi, three algae, two helminths, and one each crustacea, depletion of zooxanthellae, wound repair, hyperplasia of basal body wall, sponges, or vacuolation. Conversely, depending on the lesion, anywhere from 4 to 100% of lesion fragments did not have recognizable histological lesions (Table 3).

Cell associated microbial aggregates (CAMA) were seen in *Acropora yongei, A. Formosa, A. austera, A. muricata, A. seriata, A. paniculata, A. florida, A. mirabilis, Favia* sp., *Favites pentagona, Pocillopora meandrina, P. damicornis*, and *Porites lutea*. Of genera infected, CAMA were most prevalent in Acropora (68%, $n = 51$), Porites (57%, $n = 38$), Pocillopora (50%, $n = 4$), Favia (20%, n = 5) and Favites (17%, $n = 6$).

4. Discussion

As seen elsewhere in the Pacific, a given gross lesion in a coral can sometimes have multiple microscopic manifestations. For example, *Acropora* with tissue loss at Palmyra Atoll (Williams et al., 2010) and American Samoa archipelago (Work and Aeby, 2011) had organisms associated with lesions at the microscopic level that were similar to those seen in this study including helminths, algae, ciliates, and fungi. The same pattern applies even when a single species of coral is examined. For instance, *Montipora capitata* in Hawaii had different types of organisms associated with subacute or acute tissue loss, and these waxed and waned over time (Work et al., 2012). When broadly examining categories of lesions such as tissue loss, growth anomalies, bleaching or discoloration in this study, the variety of microscopic lesions was highest for tissue loss, followed by discoloration, bleaching, and growth anomaly, again indicating that among all lesions examined, tissue loss in corals has multiple potential causes. When broken down by categories, acute and subacute tissue loss in this study had equally variable results; however, both corals with subacute tissue loss associated with a dark band separating the lesion from normal tissues had microscopic evidence of cyanobacteria. Whilst the numbers are low, this pattern seems to replicate that seen in other band diseases in the Atlantic (Antonius, 1982; Rutzler and Santavy, 1983) and the Pacific (Sato et al., 2011) where cyanobacteria and other filamentous bacteria are prominently associated with cell pathology. Interestingly, other than filamentous bacteria, we saw no evidence of microcolonies of bacteria associated with necrosis or other host response in corals with tissue loss. This sort of lesion is typically a hallmark of bacterial-induced ulceration in epithelial surfaces of vertebrates (Marshall and Warren, 1984) and invertebrates (Leibovitz et al., 1977). The discrepancy between these findings and other papers that have incriminated bacteria as a cause of tissue loss in corals in the Pacific (Sussman et al., 2008; Ushijima et al., 2012) has been pointed out elsewhere (Work and Meteyer, 2014; Work and Aeby, 2011). Reconciling this will be difficult until experimental transmission studies attempting to replicate coral lesions in captivity incorporate examination of corals at the microscopic level to confirm or refute presence of bacteria as a cause of cell death both in the field and in captive settings.

Discoloration was also another type of lesion where microscopic findings were highly variable albeit less so than for tissue loss. For multifocal pink-to-pale discoloration, algae and inflammation were the most common microscopic findings. Other organisms such as barnacles have also been found to create multifocal pink spots on *Porites* (Benzoni et al., 2009), and not all pink spots are associated with a single agent such as larval trematodes (Aeby, 2003). However, we did find that three corals with pale-to-pink multifocal discoloration did have helminth infections, and all of these were characterized as trematodes. This is the first report of a confirmed trematode infection in *Porites* outside of Hawaii. In Hawaii, *Porites* trematodiasis is caused by parasitic larval digenetic trematodes and also presents with multifocal pink discoloration (Aeby, 1998). However, the lesions differ between regions in that trematodes in Hawaii are surrounded by a hyaline cyst, whereas this was not the case in New Caledonia. Determining whether this trematode is the same species as what occurs in Hawaii (*Podocotyloides stenometra*) would be of interest in future studies.

A mixed infection with cyanobacteria and sulfur granule-containing bacteria was seen in a single case of multifocal pale-to-pink discoloration suggesting that the presence of cyanobacteria in corals does not always manifest as a band-type disease. Cyanobacteria were also found responsible for pink discoloration in *Porites* in a disease termed Pink Line Syndrome (Ravindran and Raghukumar, 2002). The pink discoloration commonly observed on poritids can clearly be caused by a multitude of agents and is thought to play a role in coral immunity. For example, the pink discoloration in *Porites* trematodiasis was found to be a red fluorescent protein (melanin) in coral tissues in response to trematode invasion (Palmer et al., 2008), and green fluorescent protein (GFP)-like pigments were associated with repair mechanisms in *Porites lobata, Montipora foliosa and Acropora pulchra* (D'Angelo et al., 2012). Consistent with the coral immunity-pigmentation link, we also found infiltrates of inflammatory cells within the discolored tissue suggesting a role in coral immunity.

Dark discoloration was another lesion that fairly consistently (71%) presented at the microscopic level with fungi invading tissues and in some cases, the skeleton. The euendolithic origin of those discolorations is thus possible as fungi are known to be abundant in live coral skeletons (Tribollet, 2008). In general, the present findings on dark spots are in agreement with those seen in corals manifesting dark discoloration in Hawaii and American Samoa (Work et al., 2008b) suggesting that dark spots (dark discoloration) could be associated with fungi on a broader scale in the Indo-Pacific and the Caribbean (Renegar et al., 2008). The finding of this disease in New Caledonia extends its range westward from previously documented areas in the Indo-Pacific (Hawaii and American Samoa) (Work et al., 2008b).

Except for exophytic growth anomalies, over half of growth anomalies in corals presented at the microscopic level as hyperplasia of basal body wall, a pattern replicated elsewhere in corals in the Pacific (Burns and Takabayashi, 2011; Work et al., 2008a). Unlike growth anomalies of *Acropora* in the Pacific (Work et al., 2008a), we did not see necrosis in any of the growth anomalies in New Caledonia thereby highlighting the great diversity of coral responses in the case of growth anomalies across the Pacific. For diffuse bleaching, over half of cases manifested with depletion of zooxanthellae sometimes associated with necrosis. We suspect that our lack of detection of reduced zooxanthellae in some bleaching cases was due to the qualitative nature of the histologic assessment and lack of evident differences between lesion and normal tissues. Quantifying zooxanthellae in tissues would be a more sensitive indicator of bleaching but was beyond the scope of this study. In general, however, for certain lesion types such as bleaching, growth anomalies, and dark discoloration, one can be reasonably (>50%) confident that these will likely be associated with depletion of zooxanthellae for bleaching, hyperplasia of basal body wall for growth anomalies, or fungal infections for dark discoloration regardless of genera affected (Table 1).

Table 3
Percent (n) of gross lesions that have a given microscopic diagnosis for 166 coral colonies collected from New Caledonia 2010 and 2013.

	Bleaching			Discoloration			Growth anomaly					Tissue loss				Flatworm
	Diffuse	Multifocal	Focal	Multifocal	Other	Dark	Nodular	Exophytic	Rugose	Umbonate	Acute	Subacute	Chronic	Subacute band		
Histology	Primary agent															
Fungi	11 (2)	11 (1)		4 (1)	15 (2)	71 (5)				50 (1)	6 (2)	19 (5)	50 (1)			
Algae		11 (1)		38 (10)							14 (5)	8 (2)				
Helminths				12 (3)							14 (5)	12 (3)				
Ciliates											11 (4)	8 (2)				
Cyanobacteria				4 (1)							3 (1)			100 (2)		
Sponge											3 (1)	12 (3)				
Mollusc											3 (1)	8 (2)				
Crustacea								13 (1)								
Primary host response																
Depletion of zooxanthellae	53 (10)	33 (3)	33 (1)					13 (1)			3 (1)					
Hyperplasia of basal body wall							63 (5)	38 (3)	75 (3)	50 (1)						
Inflammation		11 (1)		31 (8)				13 (1)				4 (1)				
Fragmentation	5 (1)				8 (1)						14 (5)	8 (2)				
Healing							25 (2)				8 (3)	12 (3)				
Necrosis				8 (2)							11 (4)					
Mucus hyperplasia					8 (1)	14 (1)										
Vacuolation											3 (1)					100 (1)
No lesion	32 (6)	33 (3)	67 (2)	4 (1)	69 (9)	14 (1)	13 (1)	25 (2)	25 (1)		8 (3)	12 (3)	50 (1)			
Grand total	19	9	3	26	13	7	8	8	4	2	36	26	2	2		1

Host response varied with agents present. Ciliates were consistently associated with necrosis in *Montipora aequituberculata*, *Acropora florida*, *A. austera*, and *A. muricata* a pattern seen with other coral species elsewhere. For instance, ciliates in *M. capitata* with tissue loss in Hawaii were also consistently associated with necrosis (Work et al., 2012). In contrast, other agents such as algae, cyanobacteria, helminths and sponges were associated with varying host responses ranging from necrosis to fragmentation to wound repair. Inflammation also seems to be more common in certain genera. Of 22 tissue samples where inflammation (infiltration of mesogleal cells) was documented, 19 came from *Porites* and one each came from *Montipora, Millepora*, and *Sinularia*.

The findings of microcnidaria within skeletons of *Acropora* and *Porites* was a new phenomenon not seen elsewhere in the Indo-Pacific (Williams et al., 2010; Work and Aeby, 2011; Work and Rameyer, 2005). Symbiotic hydroids have been associated with surface body wall of various coral species (Montano et al., 2013; Pantos and Bythell, 2010) but not skeleton. The location of these organisms in the skeleton, the limited host response (formation of hyaline membranes), and the presence of these organisms in normal and diseased tissues, suggests they are not very pathogenic. Future studies as to their identity and effect on host would require analysis of fresh tissues for molecular and other systematic morphologic studies. Chimera have been documented in corals at the molecular level (Puill-Stephan et al., 2009) and morphologically (Work et al., 2011), so these microcnidaria could be chimera. Confirming this would require isolating these organisms, sequencing them, and comparing them to host genome.

This study expands the range of coral species harboring cell-associated microbial aggregates (CAMA) in their tissues to nine new species including *A. yongei*, *A. formosa*, *A. seriata*, *A. paniculata*, *A. florida*, *A. mirabilis*, *F. pentagona*, *Pocillopora damicornis*, and *P. lutea*. CAMA are facultative symbionts that have been documented in a wide variety of coral species throughout the Indo-Pacific and they are thought to play important roles in coral health and possibly evolution. As seen elsewhere, CAMA seem to predominate in dominant general of corals such as *Acropora*, *Porites*, and *Pocillopora* (Work and Aeby, 2014). In summary, predicting microscopic appearance of tissues or predicting presence or absence of particular organisms in coral tissues based solely on gross lesions in corals is difficult. Likewise, a given microscopic lesion may have multiple different gross manifestations. Microscopic pathology can aid in disentangling these relationships, but as evidenced by the presence of false negatives (gross lesion corals having no evident microscopic lesions) and false positives (normal fragments having microscopic lesions), this tool has its limitations. However, it does shed light on organisms associated with lesions providing additional avenues of investigations to elucidate the role of these organisms in the causation of lesions in corals. Finally, the diversity of lesions observed in corals here was comparable to that seen in corals elsewhere in the Pacific (Williams et al., 2010; Work and Aeby, 2011).

Acknowledgments

We would like to thank the South Pacific Center (CPS) in Nouméa through the program "CRISP" (Coral Reef Initiatives for the Pacific) for funding the survey in 2010, and the French Ministry of Ecology, Sustainable Development and Energy through the program "IFRECOR"(Initiative Française pour les Récifs Coralliens) for funding the survey in 2013. We also thank the Center of IRD in Nouméa for allowing us using the boat and the diving facilities. We greatly thank Miguel Clarque, Eric Folcher, Philippe Naudin, John Butscher, Armelle Renaud and Bertrand Bourgeois for their assistance on the field. We thank colleagues from the Center of IRD in Nouméa who gave us assistance and allowed the use of their

field microscopes. Mention of products or trade names do not imply endorsement by the US Government.

References

Aeby, G.S., 1998. A digenean metacercaria from the reef coral, *Porites compressa*, experimentally identified as *Podocotyloides stenometra*. J. Parasitol. 84, 1259–1261.

Aeby, G., 2003. Corals in the genus Porites are susceptible to infection by a larval trematode. Coral Reefs 22, 216.

Antonius, A., 1982. The "band" diseases in coral reefs. In: Gomez, E.D., et al., (Eds.), 4th International Coral Reef Symposium, vol. 2, Manila, Philippines, pp. 7–14.

Benzoni, F. et al., 2009. Pink spots on *Porites*: not always a coral disease. Coral Reefs 29, 153.

Bourne, D.G. et al., 2008. Identification of a ciliate (Oligohymenophorea: Scuticociliatia) associated with brown band disease on corals of the Great Barrier Reef. Appl. Environ. Microbiol. 74, 883–888.

Bourne, D.G. et al., 2009. Microbial disease and the coral holobiont. Trends Microbiol. 27, 554–562.

Burns, J.H.R., Takabayashi, M., 2011. Histopathology of growth anomaly affecting the coral, *Montipora capitata*: implications on biological functions and population viability. PLoS One 6, e28854.

Cesar, H.S.J., van Beukering, P.J.H., 2004. Economic valuation of the coral reefs of Hawai'i. Pac. Sci. 58, 231–242.

D'Angelo, C. et al., 2012. Locally accelerated growth is part of the innate immune response and repair mechanisms in reef-building corals as detected by green fluorescent protein (GFP)-like pigments. Coral Reefs 31, 1045–1056.

Fabricius, K.E., 2005. Effects of terrestrial runoff on the ecology of corals and coral reefs: review and synthesis. Mar. Pollut. Bull. 50, 125–146.

Fernandez, J. et al., 2006. A combined modelling and geochemical study of the fate of terrigenous inputs from mixed natural and mining sources in a coral reef lagoon (New Caledonia). Mar. Pollut. Bull. 52, 320–331.

Fichez, R. et al., 2010. Biogeochemical typology and temporal variability of lagoon waters in a coral reef ecosystem subject to terrigeneous and anthropogenic inputs (New Caledonia). Mar. Pollut. Bull. 61, 309–322.

Gardner, T.A. et al., 2003. Long-term region-wide declines in Caribbean corals. Science 301, 958–960.

Harvell, D. et al., 2004. The rising tide of ocean diseases: unsolved problems and research priorities. Front. Ecol. Environ. 2, 375–382.

Hoegh-Guldberg, O. et al., 2007. Coral reefs under rapid climate change and ocean acidification. Science 318, 1737–1742.

Hyman, L.H., 1940a. The invertebrates: Protozoa through Ctenophora. McGraw-Hill, New York.

Hyman, L.H., 1940b. Platyhelminthes and Rhynchocoela, the acoelomate Bilateria. McGraw-Hill, New York.

Jackson, J.B.C., 2008. Ecological extinction and evolution in the brave new ocean. Proc. Natl. Acad. Sci. 106, 11458–11465.

Larkin, J.M., Strohl, W.R., 1983. Beggiatoa, Thiothrix, and Thioploca. Ann. Rev. Microbiol. 47, 341–367.

Larone, D.H., 1976. Medically important fungi: a guide to identification. American Society for Microbiology, Washington, DC.

Leibovitz, L. et al., 1977. Necrotic exfoliative dermatitis of captive squid (*Loligo pealei*). J. Invertebr. Pathol. 30, 369–376.

Marshall, B.J., Warren, J.R., 1984. Unidentified curved bacilli in the stomach of patients with gastritis and peptic ulceration. The Lancet, 1311–1315.

McCook, L.J. et al., 2001. Competition between corals and algae on coral reefs: a review of evidence and mechanisms. Coral Reefs 19, 400–417.

Miller, A.W. et al., 2011. Fine-structural analysis of black band disease infected coral reveals boring cyanobacteria and novel bacteria. Dis. Aquat. Org. 93, 179–190.

Moberg, F.F.C., 1999. Ecological goods and services of coral reef ecosystems. Ecol. Econ. 29, 215–233.

Montano, S. et al., 2013. *Zanclea* – coral association: new records from Maldives. Coral Reefs 32, 701.

Palmer, C.V. et al., 2008. Evidence of an inflammatory-like response in non-normally pigmented tissues of two scleractinian corals. Proc. Roy. Soc. London B 275, 2687–2693.

Pandolfi, J.M. et al., 2011. Projecting coral reef futures under global warming and ocean acidification. Science 333, 418–422.

Pantos, O., Bythell, J.C., 2010. A novel reef coral symbiosis. Coral Reefs 29, 761–770.

Paulay, G., 1996. Diversity and distribution of reef organisms. In: Birkeland, C. (Ed.), Life and Death of Coral Reefs. Chapman Hall, New York, pp. 298–353.

Puill-Stephan, E. et al., 2009. Chimerism in wild adult populations of the boadcast spawning coral *Acropora millepora* on the Great Barrier Reef. PLoS One 4, e7751.

Ravindran, J., Raghukumar, C., 2002. Pink line syndrome (PLS) in the scleractinian coral *Porites lutea*. Coral Reefs 21, 252.

Raymundo, L., et al., 2008. A decision tree for describing coral lesions in the field. In: Raymundo, L., et al., (Eds.), A Coral Disease Handbook: Guidelines for Assessment, Monitoring, and Management. Coral Reef Targeted Research and Capacity Building For Management Program, St. Lucia, 2008, pp. 17–32.

Renegar, D.A., et al., 2008. Ultrastructural and histological analysis of dark spot syndrome in *Siderastrea siderea* and *Agaricia agaricites*. In: Proceedings of the 11th International Coral Reef Symposium, Ft. Lauderdale, Florida, pp. 185–189.

Roberts, C.M. et al., 2002. Marine biodiversity hotspots and conservation priorities for tropical reefs. Science 295, 1280–1284.

Ruppert, A.E. et al., 2004. Invertebrate zoology. Brooks Cole.

Rutzler, K., Santavy, D., 1983. The black band disease of Atlantic reef corals. I. Description of the cyanophyte pathogen. P.S. Z. N. I. Marine Ecol. 4, 301–319.

Sato, Y. et al., 2011. Effects of temperature and light on the progression of black band disease on the reef coral, *Montipora hispida*. Coral Reefs 30, 753–761.

Shannon, C.E., 1948. A mathematical theory of communication. Bell Syst. Tech. J. 12, 379–423.

Stanier, R.J., Cohen-Bazire, G., 1977. Phototropic prokaryotes: the cyanobacteria. Annu. Rev. Microbiol. 31, 225–274.

Sussman, M. et al., 2008. Coral pathogens identified for white syndrome (WS) epizootics in the Indo-Pacific. PLoS One 3, e2393.

Tribollet, A., 2008. The boring microflora in modern coral reef ecosystems: a review of its roles. In: Wisshak, M., Tapanila, L. (Eds.), Current Developments in Bioerosion. Springer, Berlin, pp. 67–94.

Ushijima, B. et al., 2012. *Vibrio owensii* induces the tissue loss disease Montipora White Syndrome in the Hawaiian reef coral *Montipora capitata*. PLoS One 7, e46717.

Williams, G.J. et al., 2010. Gross and microscopic morphology of lesions in Cnidaria from Palmyra Atoll, Central Pacific. J. Invertebr. Pathol. 106, 165–170.

Work, T.M., Aeby, G.S., 2006. Systematically describing gross lesions in corals. Dis. Aquat. Organ. 70, 155–160.

Work, T.M., Aeby, G.S., 2011. Pathology of tissue loss (white syndrome) in *Acropora* sp. corals from the Central Pacific. J. Invertebr. Pathol. 107, 127–131.

Work, T.M., Aeby, G.S., 2014. Microbial aggregates within tissues infect a diversity of corals throughout the Indo-Pacific. Mar. Ecol. Prog. Ser. 500, 1–9.

Work, T., Meteyer, C., 2014. To understand coral disease, look at coral cells. EcoHealth.

Work, T.M., Rameyer, R.A., 2005. Characterizing lesions in corals from American Samoa. Coral Reefs 24, 384–390.

Work, T.M. et al., 2008a. Distribution and morphology of growth anomalies in *Acropora* from the indo-pacific. Dis. Aquat. Organ. 78, 255–264.

Work, T.M. et al., 2008b. Overgrowth of fungi (endolithic hypermycosis) associated with multifocal to diffuse distinct dark discoloration of corals in the indo-Pacific. Coral Reefs 27, 663.

Work, T.M. et al., 2008c. Biomedical and veterinary science can increase our understanding of coral disease. J. Exp. Mar. Biol. Ecol. 362, 63–70.

Work, T.M. et al., 2011. Inter-specific coral chimerism: genetically distinct multicellular structures associated with tissue loss in *Montipora capitata*. PLoS One 6, e2869.

Work, T.M. et al., 2012. Tissue loss (white syndrome) in the coral *Montipora capitata* is a dynamic disease with multiple host responses and potential causes. Proc. Roy. Soc. B 279, 4334–4341.