AVIAN DISEASES 46:478–484, 2002

Case Report—

Isolation and Characterization of a Reovirus from Common Eiders (Somateria mollissima) from Finland

Tuula Hollmén,[ABE] J. Christian Franson,[B] Mikael Kilpi,[C] Douglas E. Docherty,[B] Wallace R. Hansen,[B] and Martti Hario[D]

[A]Department of Basic Veterinary Sciences, P.O. Box 57, 00014 University of Helsinki, Finland
[B]U.S. Geological Survey, National Wildlife Health Center, 6006 Schroeder Road, Madison, WI 53711
[C]Aronia Research Centre, Åbo Akademi University and Sydväst Polytechnic, Raseborgsvägen 6-8, Tammisaari, Finland
[D]Finnish Game and Fisheries Research Institute, P.O. Box 6, 00721 Helsinki, Finland

Received 19 April 1999

SUMMARY. Samples of brain, intestine, liver, lung, spleen, and bursa of Fabricius were collected from five common eider (*Somateria mollissima*) duckling carcasses during a die-off in the western Gulf of Finland (59°50′N, 23°15′E) in June 1996. No viral activity was observed in specific-pathogen-free chicken embryos inoculated with tissue suspensions, but samples of bursa of Fabricius from three birds were positive when inoculated into Muscovy duck (*Cairina moschata*) embryo fibroblasts. The isolates were characterized as nonenveloped RNA viruses and possessed several characteristics of the genus *Orthoreovirus*. Virus particles were icosahedral with a mean diameter of 72 nm and were stable at pH 3.0; their genome was separated into 10 segments by polyacrylamide gel electrophoresis. Mallard (*Anas platyrhynchos*) ducklings experimentally infected with the eider reovirus showed elevated serum activities of aspartate aminotransferase, creatine kinase, and lactate dehydrogenase enzymes and focal hemorrhages in the liver, spleen, and bursa of Fabricius. During 1997–99, the prevalence of neutralizing antibodies to the isolated virus ranged from 0 to 86% in 302 serum samples collected from incubating eider hens at three nesting areas along coastal Finland. The highest seroprevalence was found in Hanko in 1999, just weeks before reports of an uninvestigated mortality event resulting in the death of an estimated 98% of ducklings at that location. These findings raise the question of potential involvement of the virus in poor duckling survival and eider population declines observed in several breeding areas along coastal Finland since the mid-1980s.

RESUMEN. *Reporte de Caso*—Aislamiento y caracterización de un reovirus de los eíderes comunes (Somateria mollissima) de Finlandia.

Se tomaron muestras de tejidos de cerebro, intestino, hígado, pulmón, bazo y bolsa de Fabricio de los cadáveres de cinco eíderes comunes (*Somateria mollissima*) jóvenes, durante un brote de alta mortalidad ocurrido en el mes de Junio de 1996, en el golfo oriental de Finlandia (50°50′N, 23°15′E). No se observó actividad viral en embriones de pollo libres de patógenos específicos inoculados con suspensiones de tejidos, pero tres muestras de bolsa de Fabricio fueron positivas cuando se inocularon en cultivo celular de fibroblasto de pato almizclero (*Cairina moschata*). Los aislados virales fueron caracterizados como virus de tipo ARN desnudos que presentaban varias características del genero Orthoreovirus. Las partículas virales presentaban simetría icosaédrica con un diámetro promedio de 72 nm, estables a pH 3.0 y con un genoma separable en 10 segmentos mediante electroforesis en gel de acrilamida. Ánades azulones jóvenes (*Anas platyrhynchos*) infectados en forma experimental con el reovirus de los eíderes presentaron niveles elevados en las actividades de las enzimas aspartato aminotransferasa, creatinina quinasa y lactato deshidrogenasa, además de hemorragias en el hígado, bazo y bolsa de Fabricio. La prevalencia de anticuerpos neutralizantes específicos contra

[E]Present address: Alaska Sealife Center, P.O. Box 1329, Seward, AK 99664.

este reovirus, en 302 muestras de suero tomadas de eíderes hembras en tres áreas de anidamiento en las costas de Finlandia, fue de un 0% a un 86% durante el período comprendido entre los años 1997 y 1999. La prevalencia mayor de anticuerpos específicos ocurrió en muestras tomadas en Hanko en el año 1999, semanas antes del reporte de mortalidades del 98% en los patos jóvenes en esta localidad, en las cuales no se determinó el agente causal. Estos hallazgos sugieren la incidencia potencial de este virus en los bajos niveles de supervivencia de los eíderes jóvenes y la disminución del tamaño de las poblaciones de estas aves en las áreas costeras de Finlandia desde mediados de década de 1980.

Key words: common eider, Finland, *Orthoreovirus, Reoviridae,* serology, *Somateria mollissima*

Abbreviations: AST = aspartate aminotransferase; BSS = balanced saline solution; CK = creatine kinase; CPE = cytopathic effect; LDH = lactate dehydrogenase; MSDEF = Muscovy duck embryo fibroblast

The common eider (*Somateria mollissima*) is currently the most numerous species of waterfowl in the Baltic Sea of northeastern Europe (15). In the Finnish archipelago, the number of breeding pairs began to increase in the 1940s and reached an estimated maximum of about 200,000 in the 1980s (6). However, since the mid-1980s, duckling survival has dropped to as low as 1%–5% in several breeding areas in the Gulf of Finland, and, as a result, the number of breeding pairs has declined by 50% in many of these areas (6). Intestinal parasites and predation by gulls have been suggested as contributing factors in the mortality, but recent studies have concluded that alone they do not explain the high losses of ducklings in the Finnish archipelago (7,8,12,13). Lead poisoning has killed adult eiders in the Gulf of Finland, but concentrations of lead and other trace elements in duckling tissues have been relatively low (11).

Apart from serologic evidence of exposure to infectious bursal disease virus or a related virus (10), little is known about the prevalence of viruses in common eiders in Finland or potential effects of viral diseases on eider duckling survival. The aim of our study was to evaluate tissues of ducklings that died during an epizootic in the Gulf of Finland in 1996 for the presence of viruses, to test sera of adult eiders for neutralizing antibodies to viruses isolated from ducklings, and to evaluate the pathogenicity of isolated viruses in mallard (*Anas platyrhynchos*) ducklings.

CASE REPORT

Case history. In 1996, approximately 7500 common eider ducklings hatched but only about 100 fledged among our study colonies in the Tvärminne archipelago in the western Gulf of Finland (59°50′N, 23°15′E) (Fig. 1) (21). The peak hatching period for ducklings in early June was followed by a period of 2 wk (5–20 June) during which large numbers of up to 3-wk-old ducklings were found dead on eider roosting islets. Of 16 ducklings examined at necropsy, all were in poor body condition and several had hemorrhages of the liver and microscopic evidence of liver and bursal necrosis. In 1997, duckling mortality was low at our study area, and liver and bursal lesions were not found in the nine carcasses necropsied that year. Bacterial cultures were negative for pathogens, and we considered viruses as potential etiologic agents in the high mortality in 1996.

Virus isolation. Virus isolation was attempted in specific-pathogen-free chicken embryos (Spafas® Inc., Franklin, CT) (28) and Muscovy duck (*Cairina moschata*) embryo fibroblasts (MSDEFs) (2). Approximately 1-g samples of brain, intestine, liver, lung, spleen, and bursa of Fabricius from five ducklings in 1996 and nine ducklings in 1997 were homogenized in medium, and the homogenates were centrifuged at 800 × *g* for 30 min at 4 C (2). Supernatants from the homogenized samples of intestine, liver, and lung were filtered through a 0.45-μm cellulose acetate membrane filter (Corning Glass Works, Corning, NY) before the inoculations. Samples of all supernatants were inoculated separately into MSDEF monolayers, and subsamples of supernatants of brain, intestine, and lung suspensions were also inoculated into the chorioallantoic chamber of 9-day-old embryonated chicken eggs.

Embryonic viability was monitored daily for 5 days. Eggs were removed from the incubator

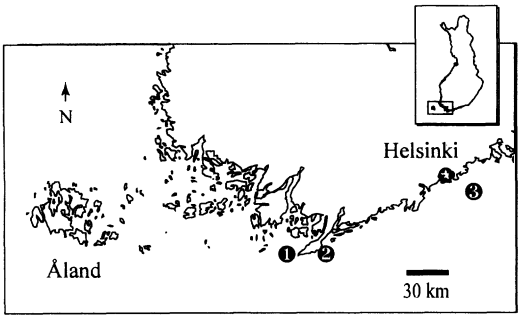

Fig. 1. Locations of breeding areas in the Baltic Sea where serum samples were collected from adult eider females. Ducklings were collected at location 2. 1 = Hanko West (59°50′N, 22°50′E); 2 = Tvärminne (59°50′N, 23°15′E); 3 = Söderskär (60°06′N, 25°25′E).

and refrigerated at 4 C when embryo mortality was observed, and all eggs remaining after 5 days of incubation were refrigerated at 4 C. Chorioallantoic fluid from each egg was tested for the presence of viruses with hemagglutination activity with chicken red blood cells (25). The cell cultures were examined every other day for 7 days for viral cytopathic effect (CPE) with an inverted stereoscopic microscope. After 7 days (or when viral CPE had destroyed 100% of the cell monolayer) the flasks were frozen at −80 C. Cell cultures that were negative for CPE were thawed, harvested, and blind passaged twice before being diagnosed negative.

No embryonic mortality was observed in the inoculated chicken eggs, and the chorioallantoic fluids from all embryos were negative in the hemagglutination test. We observed CPE and syncytia formation on the third day of incubation after the first blind passage in MSDEFs inoculated with three different bursal samples collected in 1996. All samples collected in 1997 were found negative.

Virus identification and characterization. The isolated viruses were resistant to 5-iodo-2′-deoxyuridine and chloroform treatments and were characterized as nonenveloped RNA viruses (1,3). Tissue culture fluids from positive flasks were inoculated into the chorioallantoic chambers of 9-day-old embryonated chicken eggs. All embryos died 4 or 5 days postinoculation, but chorioallantoic fluids were negative in the hemagglutination test.

We examined the ultrastructure of negatively stained virus particles with a Hitachi H500 transmission electron microscope. The particles showed icosahedral symmetry (Fig. 2) with a mean diameter of 72 nm (n = 7), consistent with the family *Reoviridae* (18). Viral RNA was extracted from infected MSDEF cell monolayers (1) and run on a 10% discontinuous Tris-glycine-sodium dodecyl sulfate–buffered polyacrylamide gel (16) to determine the number of viral genome segments. Electrophoresis was performed at room temperature for 9 hr at 20 mA. The gel was stained with ethidium bromide and photographed in an ultraviolet light transilluminator with an FCR-10 Polaroid camera (Fotodyne Inc., Hartland, WI). The genome of the virus isolate consisted of 10 segments (Fig. 3), which is consistent with the genera *Orthoreovirus* and *Orbivirus* (18,20). The virus was stable at pH 3.0, indicating that it belongs to the genus *Orthoreovirus* (14,18). A constant virus varying serum neutralization assay (30) was performed on a 96-well microplate with reference antisera to avian arthritis reovirus (Spafas® Inc.,) with MSDEF as an indicator system, but growth of the virus in cell cultures was not inhibited by avian arthritis reovirus antiserum.

Experimental inoculation of mallards. Twenty-five mallard hatchlings were housed in brooder cages in isolation rooms at the National Wildlife Health Center (Madison, WI) and fed *ad libitum* with a commercial formula for ducklings (Purina® Duck Starter; Purina Mills Inc., St. Louis, MO). At day 3, the ducklings were weighed, bled, and serum tested for neutralizing antibodies against the eider reovirus (30). The experimental ducklings were inoculated subcutaneously with 10^5 (n = 10) and 10^6 (n = 5) units of the virus determined by mean tissue culture infective dose values and diluted in Hanks balanced saline solution (BSS), and 10 ducklings were inoculated with Hanks BSS and housed separately as uninfected controls. Ducklings were monitored daily for clinical signs of illness. Two weeks postinoculation, serum was tested for neutralizing antibodies against the experimental virus, and 30% of the low-dose group and 100% of the high-dose group had seroconverted. Serum samples were also analyzed at the Central Laboratory of the Faculty of Veterinary Medicine (Helsinki, Finland) for total protein, glucose, cholesterol, triacylglycerol, uric acid, urea, alanine aminotransferase (ALT; EC 2.6.1.2), aspartate ami-

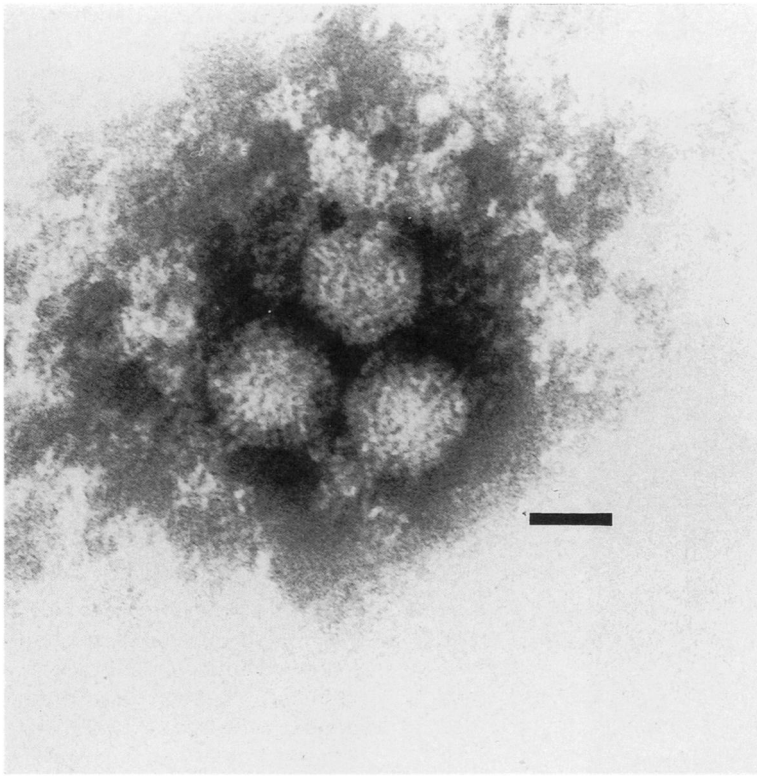

Fig. 2. Electron micrograph of the reovirus isolated from common eiders. Phosphotungstic acid staining. Bar = 50 nm.

notransferase (AST; EC 2.6.1.1), creatine kinase (CK; EC 2.7.3.2), and lactate dehydrogenase (LDH; EC 1.1.1.27). Results were compared between the groups with a Mann–Whitney *U*-test (29), and elevations in AST, CK, and LDH were found in the infected ducklings. Although no mortality occurred, pathologic findings included focal hemorrhages in the liver, spleen, and bursa of Fabricius in 40%, 13%, and 27% of the infected ducklings, respectively. Polyvalent eider reovirus antiserum obtained from experimental mallards did not inhibit the growth of avian arthritis virus S1133 in MSDEF.

Seroprevalence in adult eiders. In May of 1997–99, we collected serum samples from 302 adult female eiders at three breeding sites along coastal Finland to determine the prevalence of neutralizing antibodies to the reovirus that was isolated from the ducklings (Fig. 1). Virus neutralization assay was performed in a 96-well plate according to standard procedures (30) with MSDEF as an indicator system. The serum samples were heated at 56 C for 30 min before use and run in duplicates. The titer of the serum was determined as the highest dilution at which viral activity was inhibited on cell monolayers of both test wells. Titers of 1:128 or greater were considered positive (4).

Antibodies to the duckling reovirus were detected in adult females at each of the three breeding areas. The highest seroprevalence (86%) was found in 1999 in Hanko West, just weeks prior to an uninvestigated mortality resulting in the death of an estimated 98% of ducklings at that location (Table 1).

DISCUSSION

The virus isolated from common eider ducklings was compatible with the genus *Orthoreovirus*. The virus did not hemagglutinate chicken red blood cells, which is characteristic of most avian reovirus isolates, in contrast to the mammalian reoviruses (18). The eider reovirus probably represents a different subtype of avian reo-

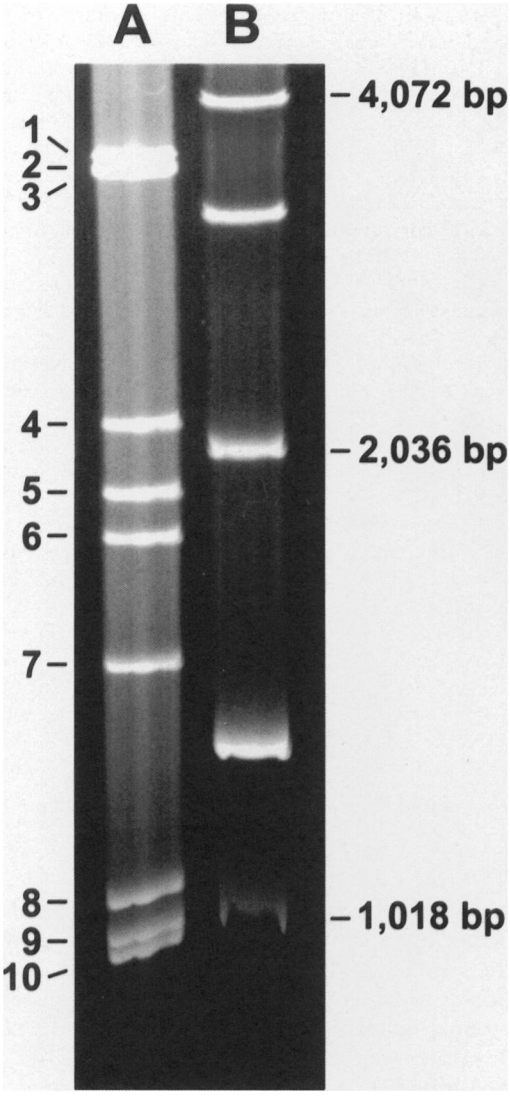

Fig. 3. RNA genome segments (1–10) of the common eider reovirus (lane A). A 1-kbp DNA ladder was used as a molecular size control in lane B. Ethidium bromide staining.

virus than that found in domestic poultry on the basis of the lack of serologic cross-reactivity with the avian arthritis virus S1133. The differences in the migration pattern of viral ds-RNA segments between the eider reovirus isolate and previously characterized avian reoviruses are not surprising because a marked heterogeneity has been demonstrated among and even within avian reovirus serotypes (5).

Reoviruses have been found in chickens and turkeys worldwide and may also be prevalent in other avian species (18,31). Although reoviruses have been isolated from asymptomatic birds, they also have been associated with a variety of disease conditions, including arthrititis/tenosynovitis, growth retardation, pericarditis, myocarditis, hydropericarditis, enteritis, hepatitis, bursal and thymic atrophy, osteoporosis, respiratory syndromes, and sudden death (18,23,24). Furthermore, reoviruses have been associated with immune system compromise (19,22), and the pathogenicity of some reoviruses has been shown to increase as a result of coinfection by coccidian parasites (26,27). Reoviruses have been reported to cause severe disease with high morbidity and up to 50% mortality in young Muscovy ducks (9,17), and they also have been associated with mortality in wild birds (1).

Table 1. Percentage (*n*) of nesting common eiders with reovirus antibody titers ≥1:128 at three study sites in the Baltic Sea.

Location	1997	1998	1999
Hanko West	10 (20)	20 (7)	86 (22)[A]
Tvärminne[B]	29 (34)	52 (54)	0 (20)
Söderskär	12 (74)	34 (47)	0 (24)

[A]Duckling mortality was 98% at Hanko West in 1999, on the basis of the number of ducklings per female at the end of the brood rearing period (see reference 21).

[B]Duckling mortality was 99% at Tvärminne in 1996 (see reference 21).

Our postmortem findings of poor body condition and necrosis of the liver and bursa in virus-positive ducklings suggest similarities with reovirus infections in chickens and Muscovy ducks (9,17,24), and we suggest that the virus found in eiders could affect duckling survival either directly or through immunosuppressive effects. The results of the seroprevalence studies indicate that eiders have been exposed to this or a closely related virus in several breeding areas along the southern coast of Finland, and, during our 3-yr study, the highest seroprevalence in breeding females coincided with high (98%) duckling mortality. At the Tvärminne study area, viruses were isolated from tissues of dead ducklings in 1996, when duckling mortality was high (99%), but not in 1997, a year of low mortality. On the basis of these findings, we believe that the eider reovirus was associated with poor fledging results at Tvärminne in 1996 and Hanko in 1999, but further research

on its pathogenicity and epidemiology is needed to evaluate the significance of neonatal reoviruses on eider populations.

REFERENCES

1. Docherty, D. E., K. A. Converse, W. R. Hansen, and G. W. Norman. American woodcock (Scolopax minor) mortality associated with a reovirus. Avian Dis. 38:899–904. 1994.

2. Docherty, D. E., and P. G. Slota. Use of Muscovy duck embryo fibroblasts for the isolation of viruses from wild birds. J. Tissue Cult. Methods 11: 165–170. 1988.

3. Feldman, H., and S. Wang. Sensitivity of various viruses to chloroform. Proc. Soc. Exp. Biol. Med. 106:736–738. 1961.

4. Giambrone, J. J. Microculture neutralization test for serodiagnosis of three avian viral infections. Avian Dis. 24:284–287. 1980.

5. Gouvea, V. S., and T. J. Schnitzer. Polymorphism of the migration of double-stranded RNA genome segments of avian reoviruses. J. Virol. 43:465–471. 1982.

6. Hario, M. Recent trends and research results for four archipelago bird species—common eider, velvet scoter, herring gull and lesser black-backed gull [in Finnish with English summary]. In: The yearbook of the Linnut magazine. T. Solonen and E. Lammi, eds. Birdlife Finland, Kuopio, Finland. pp. 12–24. 1998.

7. Hario, M., J. T. Lehtonen, and T. Hollmén. Väkäkärsämadot haahkan kuolevuustekijänä—epäilevä näkökanta [in Finnish with English summary: Role, if any, of the acanthocephalan worm Polymorphus minutus in common eider mortality]. Suom. Riista 41:21–26. 1995.

8. Hario, M., and K. Selin. Mihin haahkanpoikaset katoavat? [in Finnish with English summary: Where have all the eider ducklings gone?]. Suomen Riista 37:35–43. 1991.

9. Heffels-Redmann, U., H. Müller, and E. F. Kaleta. Structural and biological characteristics of reoviruses isolated from Muscovy ducks (Cairina moschata). Avian Pathol. 21:481–491. 1992.

10. Hollmén, T., J. C. Franson, D. E. Docherty, M. Kilpi, M. Hario, L. H. Creekmore, and M. R. Petersen. Infectious bursal disease virus antibodies in eider ducks and herring gulls. Condor 102:688–691. 2000.

11. Hollmén, T., J. C. Franson, R. H. Poppenga, M. Hario, and M. Kilpi. Lead poisoning and trace elements in common eiders Somateria mollissima from Finland. Wildl. Biol. 4:193–203. 1998.

12. Hollmén, T., M. Hario, and J. T. Lehtonen. Haahkanpoikasten massakuolema ja loisepidemia Söderskärillä 1995 [in Finnish with English summary: Description of an epizootic in eider ducklings from the Gulf of Finland]. Suom. Riista 42:32–39. 1996.

13. Hollmén, T., J. T. Lehtonen, S. Sankari, T. Soveri, and M. Hario. An experimental study on the effects of polymorphiasis on common eider ducklings. J. Wildl. Dis. 35:466–473. 1999.

14. Ketler, A., V. Hamparian, and M. Helleman. Characterization and classification of ECHO 28-rhinovirus-coryzavirus agent. Proc. Soc. Exp. Biol. Med. 110:821–831. 1962.

15. Kilpi, M. Archipelago bird populations in Finland: monitoring and recent changes. Ornis Fenn. 62:42–46. 1985.

16. Laemmli, U. K. Cleavage of structural proteins during the assembly of the head of bacteriophage T4. Nature 227:680–685. 1970.

17. Malkinson, M., K. Perk, and Y. Weisman. Reovirus infection of young muscovy ducks (Cairina moschata). Avian Pathol. 10:433–440. 1981.

18. McNulty, M. S. Reovirus. In: Virus infections of birds. J. B. McFerran and M. S. McNulty, eds. Elsevier Science Publishers B. V., Amsterdam, The Netherlands. pp. 181–193. 1993.

19. Montgomery, R. D., P. Villegas, D. L. Dawe, and J. Brown. A comparison between the effect of an avian reovirus and infectious bursal disease virus on selected aspects of the immune system of the chicken. Avian Dis. 30:298–308. 1986.

20. Nuttall, P. A. Orbiviruses associated with birds. In: Virus infections of birds. J. B. McFerran and M. S. McNulty, eds. Elsevier Science Publishers B. V., Amsterdam, The Netherlands. pp. 195–198. 1993.

21. Öst, M. Within-season and between-year variation in the structure of common eider broods. Condor 101:598–606. 1999.

22. Rinehart, C. L., and J. K. Rosenberger. Effects of avian reoviruses on the immune responses of chickens. Poult. Sci. 62:1488–1489. 1983.

23. Robertson, M. D., and G. E. Wilcox. Avian reovirus. Vet. Bull. 56:155–174. 1986.

24. Rosenberger, J. K., and N. O. Olson. Viral arthritis. In: Diseases of poultry, 10th ed. B. W. Calnek, ed. Iowa State University Press, Ames, IA. pp. 711–719. 1997.

25. Rovozzo, G. C., and C. N. Burke. Serologic techniques. In: A manual of basic virological techniques. Prentice-Hall, Inc., Englewood Cliffs, NJ. pp. 94–125. 1973.

26. Ruff, M. D., and J. K. Rosenberger. Concurrent infections with reoviruses and coccidia in broilers. Avian Dis. 29:465–478. 1985.

27. Ruff, M. D., and J. K. Rosenberger. Interaction of low-pathogenicity reoviruses and low levels of infection with several coccidial species. Avian Dis. 29: 1057–1065. 1985.

28. Senne, D. A. Virus propagation in embryonating eggs. In: A laboratory manual for the isolation

and identification of avian pathogens, 4th ed. D. E. Swayne, J. R. Glisson, M. W. Jackwood, J. E. Pearson, and W. M. Reed, eds. American Association of Avian Pathologists, Kennett Square, PA. pp. 235–240. 1998.

29. Sokal, R. R., and F. J. Rohlf. Biometry: the principles and practice of statistics in biological research, 3rd ed. W. H. Freeman, New York. 1995.

30. Thayer, S. G., and C. W. Beard. Serologic procedures. In: A laboratory manual for the isolation and identification of avian pathogens, 4th ed. D. E. Swayne, J. R. Glisson, M. W. Jackwood, J. E. Pearson, and W. M. Reed, eds. American Association of Avian Pathologists, Kennett Square, PA. pp. 255–266. 1998.

31. van der Heide, L. The history of avian reovirus. Avian Dis. 44:638–641. 2000.

ACKNOWLEDGMENTS

We thank P. Byholm, Y. Deligiannis, P. Ikonen, H. Selin, K. Selin, and M. Öst for field assistance and K. Jaquish, R. Long, and S. Nashold for technical assistance. This study was supported by a research grant from Maj and Tor Nessling Foundation.

http://www.jstor.org

LINKED CITATIONS

You have printed the following article:

Isolation and Characterization of a Reovirus from Common Eiders (Somateria mollissima) from Finland

Tuula Hollmén; J. Christian Franson; Mikael Kilpi; Douglas E. Docherty; Wallace R. Hansen; Martti Hario

Avian Diseases, Vol. 46, No. 2. (Apr. - Jun., 2002), pp. 478-484.
Stable URL:
http://links.jstor.org/sici?sici=0005-2086%28200204%2F06%2946%3A2%3C478%3AIACOAR%3E2.0.CO%3B2-Q

This article references the following linked citations. If you are trying to access articles from an off-campus location, you may be required to first logon via your library web site to access JSTOR. Please visit your library's website or contact a librarian to learn about options for remote access to JSTOR.

References

[1] **American Woodcock (Scolopax minor) Mortality Associated with a Reovirus**
D. E. Docherty; K. A. Converse; W. R. Hansen; G. W. Norman
Avian Diseases, Vol. 38, No. 4. (Oct. - Dec., 1994), pp. 899-904.
Stable URL:
http://links.jstor.org/sici?sici=0005-2086%28199410%2F12%2938%3A4%3C899%3AAW%28MMA%3E2.0.CO%3B2-S

[4] **Microculture Neutralization Test for Serodiagnosis of Three Avian Viral Infections**
J. J. Giambrone
Avian Diseases, Vol. 24, No. 1. (Jan. - Mar., 1980), pp. 284-287.
Stable URL:
http://links.jstor.org/sici?sici=0005-2086%28198001%2F03%2924%3A1%3C284%3AMNTFSO%3E2.0.CO%3B2-H

[19] **A Comparison between the Effect of an Avian Reovirus and Infectious Bursal Disease Virus on Selected Aspects of the Immune System of the Chicken**
R. D. Montgomery; P. Villegas; D. L. Dawe; J. Brown
Avian Diseases, Vol. 30, No. 2. (Apr. - Jun., 1986), pp. 298-308.
Stable URL:
http://links.jstor.org/sici?sici=0005-2086%28198604%2F06%2930%3A2%3C298%3AACBTEO%3E2.0.CO%3B2-R

NOTE: *The reference numbering from the original has been maintained in this citation list.*

http://www.jstor.org

LINKED CITATIONS

[26] **Concurrent Infections with Reoviruses and Coccidia in Broilers**
M. D. Ruff; J. K. Rosenberger
Avian Diseases, Vol. 29, No. 2. (Apr. - Jun., 1985), pp. 465-478.
Stable URL:
http://links.jstor.org/sici?sici=0005-2086%28198504%2F06%2929%3A2%3C465%3ACIWRAC%3E2.0.CO%3B2-0

[27] **Interaction of Low-Pathogenicity Reoviruses and Low Levels of Infection with Several Coccidial Species**
M. D. Ruff; J. K. Rosenberger
Avian Diseases, Vol. 29, No. 4. (Oct. - Dec., 1985), pp. 1057-1065.
Stable URL:
http://links.jstor.org/sici?sici=0005-2086%28198510%2F12%2929%3A4%3C1057%3AIOLRAL%3E2.0.CO%3B2-X

[31] **The History of Avian Reovirus**
Louis van der Heide
Avian Diseases, Vol. 44, No. 3. (Jul. - Sep., 2000), pp. 638-641.
Stable URL:
http://links.jstor.org/sici?sici=0005-2086%28200007%2F09%2944%3A3%3C638%3ATHOAR%3E2.0.CO%3B2-D

NOTE: *The reference numbering from the original has been maintained in this citation list.*