Journal of Wildlife Diseases, 19(2), 1983, pp. 162–164
© Wildlife Disease Association 1983

Squamous Cell Carcinoma in a Free-Ranging White-Tailed Deer (*Odocoileus virginianus*)

Richard K. Stroud, National Wildlife Health Laboratory, USFWS, 6006 Schroeder Road, Madison, Wisconsin 53711, USA; **and Terry E. Amundson,** Wisconsin Department of Natural Resources, Box 7921, Madison, Wisconsin 53707, USA

A 3.5-yr-old white-tailed deer was killed by wardens of the Wisconsin Department of Natural Resources after it had been observed for 3 wk in a weakened condition in or near a farmyard near Spring Green, Wisconsin. The carcass was submitted for necropsy the following day.

A 4-cm diameter necrotic ulcer impacted with fresh vegetation was observed in the right side of the hard palate (Fig. 1). Two molars from the upper right dental arcade were absent. Multiple caseonecrotic foci within the ulcer and erosion of the underlying bone were obvious when the impacted vegetation was removed. A second area of ulceration included the skin and frontal bones of the right dorsolateral surface of the muzzle. A recent pathologic fracture of the frontal bone was observed upon removal of the skin.

Examination of transverse sections of the muzzle at the level of the ulcer revealed abnormal thickening of the nasal turbinates and invasion of the surrounding structures by a cream to white, nodular, firm rubbery growth. Examination of sagittal sections of the posterior cranial vault further demonstrated the infiltra-

Received for publication 11 October 1982.

FIGURE 1. Necrotic ulcer impacted with vegetation in the hard palate of a white-tailed deer.

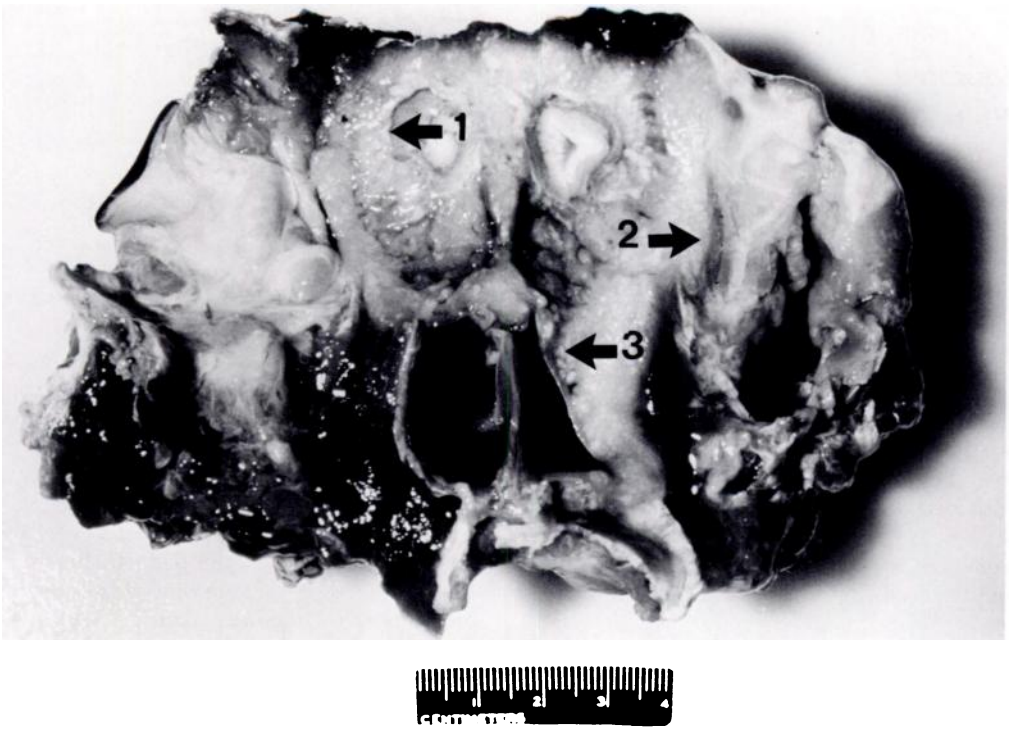

FIGURE 2. Cross section of the muzzle of a white-tailed deer showing thickening of the nasal turbinates (arrow 1), invasion of retrobulbar tissues (arrow 2), and partial occlusion of the nasal passages (arrow 3).

tion of the growth through the cribriform plate and into the subdural space of the cranium. The brain itself was not invaded. The nasal turbinates and the junction of the hard and soft palates were infiltrated so extensively by the invasive tissue that the air passages were almost completely occluded (Fig. 2). Invasion of the retrobulbar space by the growth resulted in exophthalmia.

The right retropharyngeal lymph node was enlarged, pale pink to cream-colored, firm, and nodular, and contained a few focal areas of caseous necrosis. Gross lesions indicating metastasis were not observed in the left retropharyngeal lymph node, prescapular lymph nodes, liver, spleen, or lungs.

Bloody mucus was present in the nasal cavity and trachea. Both uterine horns showed evidence of post parturient enlargement and milk was still present in the mammary tissue. The long bones were abnormally brittle and easily fractured. All fat deposits had undergone serous atrophy.

Microscopically, the tumor mass in the nasal cavity was composed of irregular masses and invasive cords of anaplastic epithelial cells (Fig. 3). Some areas of the tumor had large, central areas of necrotic debris surrounded by irregular proliferating epithelial cells. Keratinization of cells was evident but affected areas did not have the clearly defined concentric "pearls" often seen in squamous cell carcinomas. Some areas of the tumor were scirrhous, whereas others were composed of tightly packed cords of epithelial cells. The cells appeared to arise from an irregular layer, were variable in size, had discrete borders, and the nuclei contained from one to three nucleoli. Cytoplasmic vacuoles contained degenerate proteinaceous or keratinaceous material. Occasional bizarre mitotic figures were present. Fine connecting intracellular bridges were observed in some areas. The

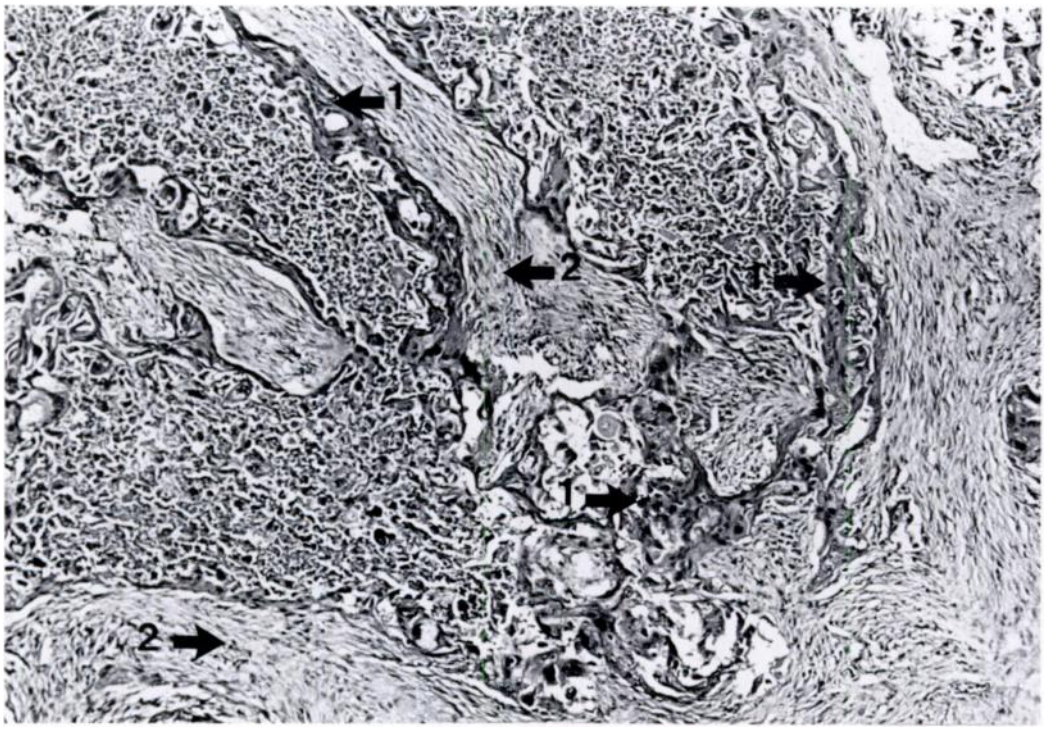

FIGURE 3. Photomicrograph of neoplastic tissue from the nasal turbinates of a white-tailed deer showing islands and cords or epithelial cells (arrow 1) in a matrix of fibrous connective tissue (arrow 2). H&E stain. ×100.

histologic characteristics of the right retropharyngeal lymph node were indistinguishable from the main tumor mass.

The origin of the tumor was not determined but could have been either the nasal or oral cavity. Squamous cell carcinomas are commonly reported in domestic mammals, but to our knowledge, have not been reported in wild deer (Cosgrove et al., 1981, *In* Diseases and Parasites of White-Tailed Deer, Davidson et al. (eds.), Misc. Pub. No. 7, Tall Timbers Research Station, Tallahassee, Florida, pp. 62–72). We could find only one other report of a squamous cell carcinoma in an Indochina Sika deer (*Cervus nippon pseudaxis*) (Ensley et al., 1980, J. Am. Vet. Med. Assoc. 177: 932).

Excluding reports of cutaneous fibromas, a relatively common viral-induced tumor in white-tailed deer, 16 forms of malignment neoplasia and 12 forms of benign neoplasia have been reported in white-tailed deer (Cosgrove et al., 1981, op. cit.). These few reports are inclusive of unpublished information on both captive and free-ranging deer. Considering the numbers of white-tailed deer harvested by hunters each year in the United States, the active management programs by conservation agencies, and the general public awareness of deer, the normal prevalence of neoplasia in deer should be greater than indicated by reports in the literature. However, predation of debilitated animals, the secretive nature of diseased individuals, the relatively young average age of heavily hunted species such as the white-tailed deer, and the few animals examined by pathologists may all be contributory to this seemingly low prevalence of reported neoplasia in wild deer herds.