Journal of Wildlife Diseases, 31(3), 1995, pp. 424-427

Probable Epizootic Chlamydiosis in Wild California (*Larus californicus*) and Ring-Billed (*Larus delawarensis*) Gulls in North Dakota

J. Christian Franson[1] **and James E. Pearson,**[2] [1] U.S. National Biological Service, National Wildlife Health Center, 6006 Schroeder Road, Madison, Wisconsin 53711, USA; [2] National Veterinary Services Laboratories, U.S. Department of Agriculture, Animal and Plant Health Inspection Service, Veterinary Services, P.O. Box 844, Ames, Iowa 50010, USA

ABSTRACT: During the summer of 1986, more than 400 California gulls (*Larus californicus*) and ring-billed gulls (*Larus delawarensis*), primarily fledglings, died on an island in Lake Sakakawea near New Town, North Dakota (USA). Mortality was attributed largely to chlamydiosis. Necropsy findings in nine carcasses included splenomegaly (n = 9), hepatomegaly (n = 4), and pericarditis (n = 1). Livers from three California gulls and two ring-billed gulls, and spleens from the same five birds plus a third ring-billed gull were positive for *Chlamydia psittaci* by the direct immunofluorescence test. *Chlamydia psittaci* was isolated from separate pools of liver and spleen from one California gull and one ring-billed gull. This is believed to be the first record of epizootic chlamydiosis in gulls and the second report of epizootic chlamydial mortality in wild birds in North America.

Key words: Chlamydiosis, *Chlamydia psittaci*, gull, *Larus californicus*, *Larus delawarensis*, epizootic.

Host records of *Chlamydia* sp. exist for at least 114 free-flying avian species, with additional reports from 37 species of birds in captivity (Burkhart and Page, 1971; Brand, 1989; Meteyer et al., 1992). Evidence of exposure to chlamydiae is most frequently reported in Charadriiformes, Passeriformes, and Anseriformes among the orders of wild birds (Brand, 1989). The organism is shed in nasal secretions and feces, and transmission probably occurs by inhalation of infected dust (Storz, 1988). Chlamydial infections often are associated with colonial nesters (Shewen, 1980), and inapparent infections are common (Kuo, 1988). Numerous reports exist of serologic evidence of chlamydial exposure or antibodies against chlamydiae in free-flying birds, but few cases of clinical disease have been reported from the wild (Brand, 1989). The only previous large-scale mortality of wild birds in North America attributed to chlamydiosis occurred in white-winged doves (*Zenaida asiatica*) in Texas (USA) (Grimes et al., 1966). We describe an epizootic of chlamydiosis involving several hundred wild California gulls (*Larus californicus*) and ring-billed gulls (*Larus delawarensis*).

On 1 August 1986, staff of the Natural Resources Department, Fort Berthold Indian Reservation, counted about 400 dead California and ring-billed gulls on an island (47°55′N, 102°20′W) in Van Hook Bay of Lake Sakakawea near New Town, North Dakota (USA). Mortality was limited almost exclusively to fledgling gulls and was restricted primarily to this 2-ha island, one of many nesting islands in Lake Sakakawea. Three more trips were made to the island during the week of 11 August 1986, but no additional carcasses were found. Human use of the island was restricted, and carcasses were collected and burned on the island.

Nine specimens, five ring-billed gulls and four California gulls, were examined at the National Wildlife Health Center, Madison, Wisconsin (USA). The carcasses, four females and five males, all were of juvenile birds. Three of these specimens were emaciated (no subcutaneous fat, marked reduction in pectoral musculature), four were in poor body condition (traces of subcutaneous fat, moderate reduction in pectoral musculature), and two were in good condition (moderate amounts of subcutaneous fat, slight or no reduction in pectoral musculature). Splenomegaly was found in all nine birds (Fig. 1). The spleen from one California gull was 15 × 70 mm, several times larger than the normal size of about 3 × 25 mm. Hepato-

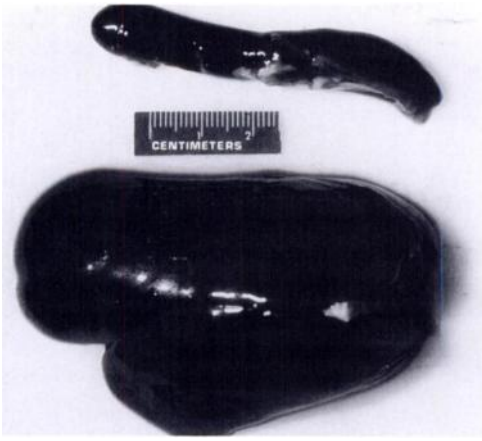

FIGURE 1. Enlarged spleen (top) and liver from a ring-billed gull (*Larus delawarensis*) with chlamydiosis.

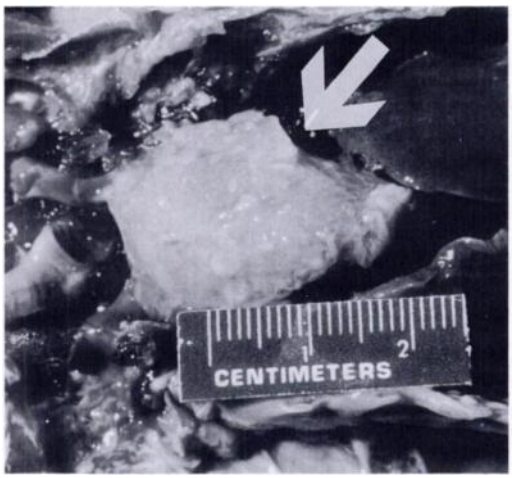

FIGURE 2. Pericarditis (arrow) in a ring-billed gull (*Larus delawarensis*) with chlamydiosis.

megaly (Fig. 1) was noted in two California gulls and two ring-billed gulls, and pericarditis (Fig. 2) was present in one ring-billed gull. Histopathologic evaluation was not possible because of the autolyzed condition of tissues.

Impression smears of liver and spleen from eight birds were examined by the direct immunofluorescence antibody technique for the detection of *Chlamydia psittaci*, as described by Tessler et al. (1979). Spleens from three ring-billed and three California gulls were positive, as were livers from the same three California gulls and two of the three ring-billed gulls. Liver and spleen samples from one California and two ring-billed gulls, from which both tissues were positive with the immunofluorescence technique, were submitted to the National Veterinary Services Laboratories (NVSL), Ames, Iowa (USA). A 10% suspension of a pool of the liver and spleen from each bird was inoculated into five embryonating chicken eggs by the yolk sac route and incubated at 37 C. Duplicate liver and spleen suspensions were inoculated onto McCoy cell cultures in shell vials (Brockway Glass Co., Inc., Decatur, Georgia, USA). The tissue suspensions were centrifuged onto the McCoy cells at 2,000 × *G* for 1 hr at 37 C, the cells were washed with Eagle's F-15 medium (Sigma Chemical Co., St. Louis, Missouri, USA), and Eagle's medium containing 1 μg/ml cycloheximide and 5% fetal bovine serum was added to the cells. The yolk sacs from all embryos that died and those remaining alive after 9 days were collected, ground in a Tenbroeck tissue homogenizer (Corning, Inc., Corning, New York, USA), and passed onto McCoy cell cultures. After 48 to 72 hr incubation at 37 C, the McCoy cells were stained with *C. psittaci* fluorescent antibody conjugate. The conjugate was produced at NVSL by hyperimmunizing a goat with an isolate of *C. psittaci* obtained from a budgerigar (*Melopsittacus undulatus*), and conjugating the antiserum with fluorescein isothiocyanate (Sigma Chemical Co.). After 72 hr the remaining cell cultures were frozen at −70 C, thawed at 23 C, and passed onto another set of McCoy cells. Incubation and staining techniques were the same as for the first passage. *Chlamydia psittaci* was isolated from the liver and spleen tissue pool of the California gull and one of the ring-billed gulls.

Portions of liver and spleen from eight carcasses were inoculated onto 5% sheep blood agar and eosin methylene blue (EMB) agar plates (Difco Laboratories,

Inc., Detroit, Michigan, USA) and incubated at 37 C for 72 hr. Bacterial isolates were identified by biochemical characteristics with the API-20E system (Analytab Products, Plainview, New York). *Salmonella* sp. was cultured from the liver and spleen of one California gull and from the livers of two ring-billed gulls. The isolates were sent to the Wisconsin State Laboratory of Hygiene, Madison, Wisconsin where all three were serotyped as *Salmonella typhimurium* according to Ewing (1986). The California gull from which *S. typhimurium* was isolated was the same bird that was positive for chlamydiosis by both the direct immunofluorescence test and chlamydial isolation. The two ring-billed gulls positive for *S. typhimurium* were negative for chlamydiosis with the direct immunofluorescence technique, and tissues were not further evaluated for chlamydiae.

Serum recovered from the heart blood of three California gulls and of two ring-billed gulls was tested for the presence of avian botulism type C toxin with the mouse protection test (Quortrup and Sudheimer, 1943). One of the five serum samples, from a California gull, was positive for botulism type C toxin. Suspensions of liver and spleen from eight carcasses were negative for the presence of viruses using embryonated chicken eggs and duck embryo cell cultures as later described by Docherty and Slota (1988).

Chlamydiosis was diagnosed in this case based on field observation of large-scale mortality consistent with rapid transmission of an infectious agent among colonial birds, the occurrence of characteristic gross lesions (splenomegaly, hepatomegaly, and pericarditis), demonstration of *C. psittaci* by the direct immunofluorescence test, and isolation of *C. psittaci* from tissues. Although we believe chlamydiosis to be the most significant finding in this event, there is a potential contributory role of salmonellosis based on the isolation of *S. typhimurium* from three of the carcasses examined. Avian botulism type C probably did not contribute significantly to this epizootic because botulism toxin was found in only one of five gulls tested and the positive carcass was somewhat autolyzed, increasing the likelihood that toxin formation was post-mortem (Reed and Rocke, 1992).

Chlamydiae are very successful in producing inapparent infections in their hosts (Manire, 1981). Many reports of chlamydial exposure in wild birds have come from serologic surveys, but few records exist of mortality in free-living birds, particularly on a large scale (Burkhart and Page, 1971; Brand, 1989). Individual mortalities may be noticed infrequently because carcasses often are removed by other animals (Stutzenbaker et al., 1986). Because a large number of gulls died on a small island with few scavengers, this event was noticed and investigated. This is believed to be the first record of epizootic chlamydiosis in wild gulls in North America and only the second report of epizootic chlamydial mortality in free-flying birds on this continent.

A. McKay investigated and reported this event and A. Ludden coordinated shipment of carcasses. R. Windingstad and K. Converse contributed advice on disease control measures. R. Duncan and D. Docherty provided laboratory support. C. Brand, J. Fischer, D. Forrester, L. Glaser, L. Locke, and V. Nettles provided helpful comments on the manuscript.

LITERATURE CITED

BRAND, C. J. 1989. Chlamydial infections in free-living birds. Journal of the American Veterinary Medical Association 195: 1531–1535.

BURKHART, R. L., AND L. A. PAGE. 1971. Chlamydiosis (ornithosis-psittacosis). *In* Infectious and parasitic diseases of wild birds, J. W. Davis, R. C. Anderson, L. Karstad, and D. O. Trainer (eds.). Iowa State University Press, Ames, Iowa, pp. 118–140.

DOCHERTY, D. E., AND P. G. SLOTA. 1988. Use of muscovy duck embryo fibroblasts for the isolation of viruses from wild birds. Journal of Tissue Culture Methods 11: 165–170.

EWING, W. H. 1986. Edwards and Ewing's identification of Enterobacteriaceae, 4th ed. Elsevier Science Publishing Co., Inc., New York, New York, pp. 247–318.

GRIMES, J. E., T. D. SULLIVAN, AND J. V. IRONS. 1966. Recovery of ornithosis agent from naturally infected white-winged doves. The Journal of Wildlife Management 30: 594–598.

KUO, CHO-CHOU. 1988. Host response. *In* Microbiology of chlamydia, A. L. Barron (ed.). CRC Press, Boca Raton, Florida, pp. 193–208.

MANIRE, G. P. 1981. The Chlamydiae. *In* Medical microbiology and infectious diseases, A. I. Braude (ed.). W. B. Saunders Co., Philadelphia, Pennsylvania, pp. 516–522.

METEYER, C. U., R. P. CHIN, A. E. CASTRO, L. W. WOODS, AND R. P. GENTZLER. 1992. An epizootic of chlamydiosis with high mortality in a captive population of euphonias (*Euphonia violaceas*) and hummingbirds (*Amazilia amazilias*). Journal of Zoo and Wildlife Medicine 23: 222–229.

QUORTRUP, E. R., AND R. L. SUDHEIMER. 1943. Detection of botulinus toxin in the bloodstream of wild ducks. Journal of the American Veterinary Medical Association 102: 264–266.

REED, T. M., AND T. E. ROCKE. 1992. The role of avian carcasses in botulism epizootics. Wildlife Society Bulletin 20: 175–182.

SHEWEN, P. E. 1980. Chlamydial infection in animals: A review. Canadian Veterinary Journal 21: 2–11.

STORZ, J. 1988. Overview of animal diseases induced by chlamydial infections. *In* Microbiology of chlamydia, A. L. Barron (ed.). CRC Press, Boca Raton, Florida, pp. 167–192.

STUTZENBAKER, C. D., K. BROWN, AND D. LOBPRIES. 1986. Special report: An assessment of the accuracy of documenting waterfowl die-offs in a Texas coastal marsh. *In* Lead poisoning in wild waterfowl—A workshop, J. S. Feierabend and A. B. Russell (eds.). National Wildlife Federation, Washington, D.C., pp. 88–95.

TESSLER, J., S. S. STONE, AND L. A. PAGE. 1979. Direct immunofluorescence tests with counterstains for detection of *Chlamydia psittaci* in infected avian tissues. Canadian Journal of Comparative Medicine 43: 217–222.

Received for publication 12 September 1994.