J Vet Diagn Invest 9:269-280 (1997)

Sodium toxicity and pathology associated with exposure of waterfowl to hypersaline playa lakes of southeast New Mexico

Carol U. Meteyer, Richard R. Dubielzig, F. Joshua Dein, Laurie A. Baeten, Melody IS. Moore, Joseph R. Jehl, Jr., Katherine Wesenberg

Abstract. Cause of mortality was studied in waterfowl in hypersaline playa lakes of southeast New Mexico during spring and fall migration. Mortality was not common in wild ducks resting on the playas during good weather. However, when birds remained on the lakes for prolonged periods of time, such as during experimental trials and stormy weather, a heavy layer of salt precipitated on their feathers. Sodium toxicity was the cause of death for all experimental mallards housed on playa water and for 50% of the wild waterfowl found moribund or dead during the spring of 1995. Gross lesions included heavy salt precipitation on the feathers, ocular lens opacities, deeply congested brains, and dilated, thin-walled, fluid-filled cloacae. Microscopic lesions in the more severely affected birds included liquefaction of ocular lens cortex with lens fiber swelling and multifocal to diffuse ulcerative conjunctivitis with severe granulocytic inflammation, edema, and granulocytic vasculitis resulting in thrombosis. Inflammation similar to that seen in the conjunctiva occasionally involved the mucosa of the mouth, pharynx, nasal turbinates, cloaca, and bursa. Transcorneal movement of water in response to the hypersaline conditions on the playa lakes or direct contact with salt crystals could induce anterior segment dehydration of the aqueous humor and increased osmotic pressure on the lens, leading to cataract formation.

Under natural circumstances, playa lakes of arid regions are ephemeral. As they evaporate, the water becomes increasingly saline, ultimately resulting in the natural accumulation of evaporates/precipitates. Prior to 1940, typical playa lakes characterized the southeast corner of New Mexico, representing a Permian marine basin that became restricted approximately 255 million years ago by the massive Capitan Reef and subsequently filled with evaporites rich in potash. Early in the 1940s brine discharge from regional potash and oil industries created new playas and turned these and some natural playas into more permanent bodies of water[3] available for use by migrant waterfowl all year. The Lea and Eddy counties region has been the largest potash mining area in the United States[3] with 6 potash mines still in operation. Migratory waterfowl land on the playa lakes in spring and fall. Reports of wild bird mortality in the region initiated this investigation to determine the cause of death.

The natural but discharge-modified playas studied were Laguna Toston and Williams Sink. Field surveys were also performed at Lagunas Uno, Dos, Tres, and Quatro in Nash Draw. The Nash Draw playas may have surface connections or connections via the locally high ground water table.[7,13,28] Each year, Nash Draw receives approximately 1.8 x 10^6 metric tons of NaCl from potash industry discharge[7] and > 9,000 acre feet of water imported from the Ogallala aquifer.[13] Total dissolved solids in Williams Sink and Laguna Toston measured during spring 1995 were 201,000 ppm and 316,000 ppm, respectively, and total dissolved solids in Lagunas Uno, Dos, Tres, and Quatro during spring 1995 were 295,000 ppm, 298,000 ppm, and 303,000 ppm, respectively.[27] Sodium and chloride are the primary ions in all playas, which also contain significant amounts of potassium, sulfate, and magnesium.[27] Reports of salinity of the playa lakes prior to the initiation of potash mining could not be found. Total dissolved solids in sea water is approximately 30,000 ppm.

The landscape bordering Lagunas Toston, Uno, Dos, Tres, and Quatro is exposed, flat, and barren. A thick salt pan substrate covers the playa bottom, shore, and surrounding ground, and there is little or no vegetation along the shore. Williams Sink differs in that it occupies a protected depression with a loam/silt and gypsum sand bottom, and the surrounding shore has relatively dense vegetation. Fine deposits of crystalline salts were visible only on vegetation and debris around Williams Sink.[7] Williams Sink was also the only playa with a substantial population density of benthic microinver-

From the National Wildlife Health Center, Biological Resource Division, U.S. Geological Survey, Madison, WI 53711 (Meteyer, Dein, Baeter, Moore, Wesenberg), the Department of Pathobiological Sciences, School of Veterinary Medicine, University of Wisconsin, Madison, WI (Dubielzig), and Hubbs-Sea World Research Institute, 2595 Ingraham Street, San Diego, CA 92109 (Jehl)

Received for publication October 14, 1996.

tebrates, diatoms, and phytoplankton when evaluated in 1992.[7] Williams Sink has not received direct potash discharge since 1982 but runoff from a large potash tailings pile was reaching the southeastern corner of the basin in 1992, at which time the total dissolved solids at William sink was 169,000 ppm.[7]

Materials and methods

Experimental investigations. In fall 1994, an experimental study at Laguna Toston and Williams Sink to determine the effect of playa water on farm-reared mallards (*Anas platyrhynchos*)[a] was conducted. Ducks were acclimated to pens, gravity waterers, and gravity feeders and provided commercial duck chow *ad libitum.* Laguna Toston was chosen as a site currently receiving effluent from a potash plant. Williams Sink was chosen as a modified control site because it has not been used for potash discharge since 1982. Both Laguna Toston and Williams Sink had three study groups of 5 mallards each; group 1 was housed on playa water, group 2 was housed on land adjacent to the playa and given only playa water to drink, and group 3 was housed on land adjacent to the playa and provided fresh drinking water. Mallards were monitored for 48 hr, continuously during the day and intermittently through the night, and shipped to the National Wildlife Health Center (NWHC) for necropsy at death, after euthanasia due to distress, or after euthanasia at the end of the 48hr observational period. Mallards were individually packaged in plastic bags and shipped on ice packs via overnight delivery.

Field investigations. Field biologists surveyed Williams Sink and Lagunas Toston, Uno, Dos, Tres, and Quatro for sick or dead birds from March 9 through April 25, 1995. There were 75 survey periods during this time totalling 275 observational hours. Birds unable to fly or escape capture were euthanized and shipped with birds found dead to the NWHC as described for the experimental birds. Clinical signs and weather conditions were recorded. Carcasses were received from all playas listed above except Williams Sink.

Necropsy. Necropsies followed a standard protocol to insure complete and uniform testing of 64 waterfowl. To determine the weight of the salt precipitate on the carcasses, pre-rinse and post-rinse carcass weights were taken and the calculated difference was determined to be the approximate weight of salt precipitate. Salt for composition analysis was collected from random birds prior to rinsing. Birds were considered immature if a bursa of Fabricius was present.

To prevent contamination of brain tissue with salt from carcasses or instruments, the carcass was thoroughly rinsed away from the necropsy surface. Instruments were prepared in advance by thoroughly washing, soaking overnight in 5% nitric acid, and rinsing in 3 separate beakers of double-deionized water (acid-washed instruments). The skin of the ventral surface of the neck was incised longitudinally and cut circumferentially in the midcervical region. With an assistant providing traction, the pathologist used clean gloves[b] to reflect the skin from the midcervical region over the neck and head, providing a clean subcutaneous and skull surface that had not been touched by instruments or gloves. Gloves were changed, and new acid-washed instruments were used to cut and remove the dorsal surface of the skull, inserting the tip of the scissors into the skull only once. A portion of the brain was removed and placed directly into single-use sterile sampling bags[c] using an acid-washed plastic spoon. A preliminary study using the above protocol with 14 7-wk-old normal broad-breasted white turkey poults determined no significant differences between brain sodium concentrations analyzed in parallel for samples placed in acid-washed jars and those placed in the sample bags.

Histopathology. Samples of brain, glottis, nasal turbinates, hard palate eyelid, eye, salt gland, adrenal gland, kidney, heart, trachea, air sacs, lung, spleen, bursa of Fabricius, liver, pancreas, tongue, esophagus, crop, proventriculus, ventriculus, intestine, cloaca, foot web, and occasionally bone marrow and syrinx were collected for histopathology. Tissues were placed in 10% neutral buffered formalin for approximately 24 hr before being trimmed for processing. Formalin-fixed tissues were embedded in paraffin, sectioned at 5 µm, and stained with hematoxylin and eosin (HE). Eyes from euthanized waterfowl were fixed in Bouin's solution (0.9% picric acid, 5% acetic acid, 3.9% formalin) for approximately 24 hr, rinsed in cold tap water for 15 min, and transferred to 70% ethanol prior to trimming and embedding in paraffin. Bony tissues were decalcified in decalcifying solution[d] for 6-24 hr prior to trimming and embedment.

Chemistry. Brain analysis for sodium was determined by inductively coupled plasma emission (ICP) following standard protocols.[33] Any bird with a brain sodium concentration ≥ 2,000 ppm wet weight was considered to have died from sodium poisoning;[34] however, brain sodium concentrations > 10,000 ppm wet weight were considered to be above a reasonable physiological level in a bird dying from sodium poisoning, and the sample was considered contaminated. Water was analyzed for total dissolved solids and metals by atomic absorption spectrophotometry using standard methods,[27] and pH of the water was determined using a Corning pH meter[e] that was buffered against pH 7.00 buffer.[e] Analysis of salt composition from feathers was performed by ICP analysis.[33] Brains of 28 waterfowl were analyzed for cholinesterase activity. Cholinesterase assays were performed in duplicate using methods previously described.[10,15] Cholinesterase inhibition was reported if mean cholinesterase activity was below the diagnostic threshold, i.e., 2 standard deviations below the mean NWHC reference value for the species being tested. Livers from 9 birds were analyzed for lead using standard methods.[22]

Bacteriology. Livers from 56 birds were cultured for aerobic bacteria using 5% sheep blood agar and eosin-methylene-blue agars.[f] Inoculated plates were incubated at 36 C for 48 hr. Intestine was also cultured from 10 birds for *Salmonella* sp. using selenite broth (with dulcitol substituted for lactose)[f] incubated at 36 C for 24 hr and subcultured on xylose-lysine-desoxycholate and brilliant green agars.[f] Identity of bacterial isolates was determined using the a commercially available detection system.[9] Botulism tests were conducted on heart blood from 30 waterfowl using the standard mouse toxicity test.[26]

Virology/serology. Virus isolation was attempted with intestine and lung from 13 birds. Tissues were inoculated into

muscovy embryo fibroblast cell cultures[8] and embryonating hen's eggs via the allantoic sac route.[29]

Results

Field observations

Experimental mallards. Within 5 minutes of placement on Laguna Toston water, mallards began dipping their heads under water, flicking their beaks, shaking their heads and tails, and rubbing their heads over their backs. Preening behavior was almost constant early in the observation period. Salt deposition on feathers was noted 3 hours after mallards were placed on Laguna Toston. At 3 hours, birds began to huddle quietly with very little activity and appeared depressed, and 1 mallard turned in continuous slow, tight circles. Birds were heavily salt encrusted within 24 hours. Blepharitis, chemosis, and prolapse of the nictitating membrane was observed associated with frequent blinking. Torticollis was seen when the mallards were close to death. One mallard was found dead at Laguna Toston 11 hours after placement on playa water, the other 4 mallards placed on Laguna Toston were found dead between 20 and 22 hours after placement. Winds reached 90 km/hr during the study at Laguna Toston.

Mallards at Williams Sink had less salt precipitation and clinical signs developed later than in those housed on Laguna Toston water. Williams Sink mallards tended to do more quiet floating and dipped their beaks but did not aggressively preen their feathers. Salt had formed a thin precipitate over the head of the mallards after 3 hours on the sink. Blepharitis, chemosis, and prolapse of the nictitating membrane with frequent blinking was also seen 3 hours after placement, and head shaking was common 7 hours after placement. Circling behavior was seen in 1 mallard 11 hours after placement. One mallard brought on land for observation 13 hours after placement was "star-gazing" with torticollis and subsequently would fall onto its back. All mallards placed on Williams Sink were euthanized between 24 and 35 hours after placement. No unusual weather or winds occurred during the trial at Williams Sink.

No abnormal clinical signs or notable salt precipitation was observed for any of the study groups housed on land regardless of the playa to which they were assigned or whether they were provided playa water or fresh water for drinking.

Wild waterfowl survey. A total of 1,579 waterfowl (21 species) were observed landing on playa water during survey times. Except for a single passerine, all of the carcasses represented waterfowl, including coot and 8 species of duck (Table 1). Although 340 shorebirds and gulls (7 species), were present in low numbers, none were found dead or moribund. Waterfowl appeared in good condition when they arrived on the playas, and most departed at nightfall without effect. For those that arrived or remained in severe weather, salt spray could be seen precipitating on feathers within minutes of landing. Salt formed an obvious layer over the feathers within 3 hours and was followed by rapid encrustation preventing evening departure of the birds. As salt deposition increased, preening and head-rubbing over the back, followed by bill shaking became more frequent. Prolonged preening was sometimes accompanied by feather pulling or consecutive dives into the water followed by wing-flapping. Seventy percent of all wild bird submissions were associated with 2 storm events occurring on April 11 and 17, 1995, with 80-100 km/hr winds and choppy water. Twenty-two birds were euthanized during the field surveys, and 18 of the euthanized waterfowl were found moribund after the April 11 and April 17, 1995 storm events. Euthanized waterfowl were found mobile but unable to fly; many did not attempt escape when approached and some were severely depressed and uncoordinated.

Necropsy

Experimental mallards. All mallards were immature males in fair to good body condition. Control birds housed on land had no salt precipitate on feathers. When rinsed with water, the control birds, without salt on feathers, gained an average of 40 g of water weight. Salt precipitation on carcasses from mallards housed on playa water at Williams Sink was light, and all birds gained weight with rinsing indicating the salt that had precipitated on the feathers was less than the average 40 g of water the carcasses were gaining due to rinsing (Table 1). Mallards housed on playa water at Laguna Toston were encrusted with salt deposits up to 2.5 cm thick over the wings, tail, back,. and shoulders (Fig. 1). Salt on the Laguna Toston mallards weighed up to 1,955 g and was more than the rinsed body weight of 4 of the 5 experimental birds on Laguna Toston (Table 1; salt precipitate expressed as percentage of body weight). The average salt precipitated on the Laguna Toston mallards was 1,250 g. The average body weight of the mallards housed on the playa water was 1,080 g (range, 960-1260 g). Down feathers were dry on all birds in spite of the heavy salt deposit on feathers.

The mucosa of pharynx and glottis were reddened in mallards housed on playa water. The conjunctiva and nictitating membrane were reddened and swollen, and there was a small amount of serous conjunctival fluid. The eyes were difficult to evaluate in some birds because of prolapse of the nictitating membrane, making removal of the globe necessary for visualization of the lens. All birds housed on Lacuna Toston and Wil-

Table 1. Findings from experimental mallards from Laguna Toston and Williams Sink, 1994, and wild waterfowl from field surveys (Field) of the playa lakes, spring 1995. Microscopic lens and conjunctival lesions were classified as normal (0) mild (1), moderate (2) or severe (3).

Species	Date collected	Euthanized	Brain Na (ppm)	SPT* (% body wt)	Cataract	Conjunctivitis
Experimental Toston						
Mallard	11/16/94	no	2,034	152	–†	2
Mallard	11/16	no	2,170	103	2	3
Mallard	11/15	no	2,634	12	2	2
Mallard	11/16	no	2,201	109	2	3
Mallard	11/16	no	2,414	176	3	2
Wm Sink						
Mallard	11/19	yes	2,989	<4	1	2
Mallard	11/19	yes	2,618	<4	3	2
Mallard	11/19	yes	3,231	<4	1	3
Mallard	11/19	yes	2,424	<4	1	2
Mallard	11/19	yes	2,896	<4	1	3
Field Toston						
N. shoveler	4/11/95	no	1,708	45	2	0
N. shoveler	4/11	no	1,744	125	2	2
N. shoveler	4/11	yes	2,213	47	2	1
N. shoveler	4/11	yes	1,847	111	1	0
N. shoveler	4/11	yes	1,853	53	2	0
N. shoveler	4/11	yes	1,670	12	2	0
N. shoveler	4/11	yes	1,638	34	1	0
N. shoveler	4/11	yes	2,002	64	3	0
N. shoveler	4/11	yes	2,037	89	3	–‡
N. shoveler	4/11	yes	2,030	39	3	0
N. shoveler	4/11	yes	3,511	45	3	0
N. shoveler	4/11	yes	2,197	63	1	0
N. shoveler	4/17	yes	1,596	31	1	0
N. shoveler	4/17	yes	2,123	70	3	1
N. shoveler	4/17	yes	1,876	78	1	0
N. shoveler	4/17	yes	1,859	61	2	0
N. shoveler	4/17	yes	2,195	62	3	0
N. shoveler	4/17	yes	2,800	77	3	0
Green-winged teal	4/11	no	2,625	53	1	0
Green-winged teal	4/11	yes	2,132	21	1	0
Green-winged teal	4/11	yes	2,067	28	0–1	0
Green-winged teal	4/11	no	2,849	98	1	0
Blue-winged teal	4/17	no	lost	34	3	0
L. scaup	4/11	no	2,680	163	–†	1
L. scaup	4/11	no	1,960	102	–†	1
Gadwall	4/11	no	1,764	97	1	0
Gadwall	4/23	yes	1,623	15	1	0
Ruddy duck	4/20	no	2,179	105	2	0
Ruddy duck	4/25	no	2,030	78	3	2
American Coot	3/20	no	1,800	S	1	1
Laguna Uno						
L. scaup	4/4	yes	1,636	15	1	2
L. scaup	4/7	yes	1,530	12	0–1	2
Laguna Dos						
L. scaup	4/12	no	14,645	5	–†	3
L. scaup	3/22	yes	2,293	R	1	–‡
Crissal Thrasher	3/22	no	32,811	<4	3	0
Laguna Tres						
Wood duck	3/12	no	2,808	78	1	1
Laguna Quatro						
Shoveler	4/12	no	29,268	14	–†	–‡

* Salt precipitate on carcass. S = scavenged; R = rinsed before arrival.
† Poor condition, could not interpret.
‡ Sample not taken.



Figure 1. Salt-encrusted experimental mallard housed on Laguna Toston.

liams Sink had ocular lens opacities; 1 mallard on Williams Sink had only mild lens opacity. Meningeal vessels were congested and brain parenchyma was uniformly deep red in all mallards housed on playa water (see Fig. *3F*). Retrobular tissue and turbinate mucosa was congested and a mild amount of red-tinged mucus was present over the nasal turbinates in some ducks. Abundant foamy, serosanguineous fluid flowed from the cut surface of lungs from birds that died spontaneously, but lungs floated in formalin. Pulmonary edema was not seen in birds that were euthanized. Some proventriculi contained a moderate amount of mucus. The intestinal wall was congested and the cloaca was often dilated and thin walled, containing golden fluid. Pectoral muscle was deep red and tacky, suggesting dehydration. Subcutaneous edema was seen at the thoracic inlet in 1 of 5 mallards housed on Williams Sink.

There was no obvious salt precipitation and no external or internal gross lesions in the mallards housed on land. The feet and footwebs were unremarkable for land- and water-based mallards, and no fecal material was seen on the feathers around the vent. The bursa of Fabricius was grossly unremarkable when present. Salt glands were also unremarkable in both land- and water-based birds.

Field survey waterfowl. All waterfowl submitted for necropsy were adults in good body condition with moderate to abundant body fat and adequate pectoral muscle. Birds from Laguna Toston had moderate to heavy salt precipitation on the feathers (Table 1), with quantities ranging from 100 g on a 280-g green-winged teal to 1,175 g on a lesser scaup weighing 695 g. The average weight of salt on the birds from Laguna Toston was 370 g. Average weight of precipitate on waterfowl from Lagunas Uno, Dos, Tres, and Quatro was 133 g, 47 g, 372 g, and 115 g, respectively. Waterfowl from each playa had lesions similar to those seen in the experimental mallards housed on playa water. Congested brains were seen in 24 of 37 birds and opaque lenses were seen in 18 of 37 birds. Ocular lens opacities were bilateral in 16 birds and unilateral in 2 birds. Thin-walled, dilated, fluid-filled cloacae, often 2-3 cm in diameter, were seen in 24 of 37 wild birds.

Histopathology

Experimental mallards. Significant pathology was seen only in the mallards housed on playa water. The most severe and consistent microscopic changes were associated with the lens (Table 1) and the mucosa of conjunctiva, turbinates, hard palate, pharynx, bursa of Fabricius, and/or cloaca (Table 2). Lens opacities were graded as 1, 2, or 3. In grade 1 (mild) lesions, granular eosinophilic debris accumulated between the anterior capsule and lens cortex. Equatorial and anterior cortical lens fibers were swollen in the optical region of the lens and in the lens pad; fiber swelling was limited to the anterior aspect (Fig. 2B). In grade 2 (moderate) lesions, the anterior lens pad was partially disrupted and granular eosinophilic debris formed a thick liquified zone underneath the anterior capsule. Lens fibers

Table 2. Number of birds exhibiting mucosal lesions, as a sample of experimental and wild waterfowl landing on the playa lakes of southeast New Mexico.

Tissue	*n*	Granulocytic inflammation	Necrosis/ulceration	Vasculitis	Thrombi
Experimental birds					
Conjunctiva	10	10	10	10	9
Glottis	3	3	3	2	2
Trachea*	3	1	1	1	0
Turbinate	10	9	5	3	1
Hard Palate	10	8	3	0	0
Bursa	5	4	4	1	0
Field specimens					
Conjunctiva	34	11	7	5	2
Glottis	33	9	9	1	0
Trachea*	33	6	6	1	0
Turbinate	35	10	4	5	1
Hard palate	36	9	9	1	0
Cloaca	21	6	2	2	2

* Ventral mucosa of proximal trachea at the opening of the glottis.

were swollen in the equatorial and anterior cortex (Fig. 2C). Grade 3 (severe) lesions in the lens included extensive damage and liquefaction of lens pad with a thick zone of eosinophilic debris in the lens cortex, sometimes extending circumferentially around the lens (Fig. 2D). The cornea and ciliary body of some birds had a multifocal mild infiltrate of granulocytes.

Microscopic sections of conjunctiva from mallards housed on playa water had multifocal to diffuse coagulative necrosis with fibrin adhered to the ulcerated surface (Fig. 3A). Marked edema and mild hemorrhage in the submucosa was associated with dense populations of granulocytes containing large, round eosinophilic granules (Fig. 3B). These granules were often free in surrounding tissue, suggesting degranulation. The morphology of multifocal submucosa1 vessels was often obscured by dense infiltration of large granulocytes. Some of these vessels had brightly eosinophilic fibrinoid necrosis of the wall with thrombosis (Fig. 3C). Lympholysis was seen when conjunctiva-associated lymphoid tissue was present in the section.

Turbinate epithelium was multifocally ulcerated in some mallards with granulocytic inflammation and vasculitis (Fig. 3E) and hemorrhage into the lumen. Thrombosis of turbinate vessels was seen in 1 mallard.

The pharyngeal surface of the glottis often had severe coagulative necrosis with ulceration, submucosal edema, and striking granulocytic inflammation in the submucosa. Vessel walls were occasionally infiltrated by granulocytes, and thrombi were present in vessels of some of these submissions. Colonies of mixed bacteria could occasionally be seen over the ulcerated pharyngeal surface. Occasionally, the ventral surface of the respiratory glottis, just ventral to the tracheal opening, was ulcerated with adherent fibrin, submucosal edema, granulocytic inflammation, fibrinoid necrosis of multifocal vessels, and severe granulocytic inflammation within the vessel wall.

The superficial epithelium of the bursa of Fabricius was ulcerated with a dense layer of granulocytes along the surface and in the submucosa. Granulocytic vasculitis was seen in the bursa of 1 out of the 5 experimental mallards on playa water with bursa evaluated.

Vessels in the brain were congested with occasional mild multifocal perivascular hemorrhage and irregular perivascular spaces; however, these changes were inconsistent and nonspecific.

The lungs of experimental birds that died on water had a moderate amount of eosinophilic proteinaceous material in the air spaces and scattered alveolar macrophages with foamy cytoplasm, suggesting edema. The bronchi and trachea often had mild granulocytic mucosal inflammation, which was more prominent in experimental birds that survived the longest, particularly the mallards housed on land. Oral mucosa and esophagus occasionally contained nematodes resembling *Capillaria* sp., but there was no significant associated inflammation in the ducks housed on land, and these nematodes were thought to be incidental. The liver of some birds housed on playa water had mild bile stasis, and scattered hepatocytes were pyknotic. Mild pancreatic apoptosis was present in mallards housed on playa water and mallards housed on land but provided playa water to drink. Mild hemosiderin pigment in hepatocytes was seen in mallards from each study group. Salt glands were unremarkable in all birds.

Ten mallards, 5 housed on playa water and 5 housed on land, had splenic amyloid which was mild in 9 and severe in 1 mallard. Splenic amyloid was thought to be an incidental preexisting condition.

Field survey *waterfowl.* Changes seen in the experimental mallards were also observed in wild waterfowl collected at each of the 5 playas surveyed. Of the 30 waterfowl evaluated from Laguna Toston, all had peracute cataracts ranging from mild (12) to moderate or severe (16) (Table 1). Postmortem artifact precluded interpretation of the lens lesions in 2 of the birds. Although changes observed in the lens of the eye were consistent with those seen in experimental mallards, pathology of mucosal surfaces (Fig. 3D) was less severe than that in experimental birds (Table 2). Pulmonary edema was present in waterfowl that died spontaneously but was not a characteristic finding in birds that were euthanized. Vacuolation of renal tubule epithelium was seen in 20 of 29 wild waterfowl (11 of 18 with brain sodium concentration in the toxic range and 2 with brain sodium concentrations indicating contamination) but was not seen in the experimental mallards.

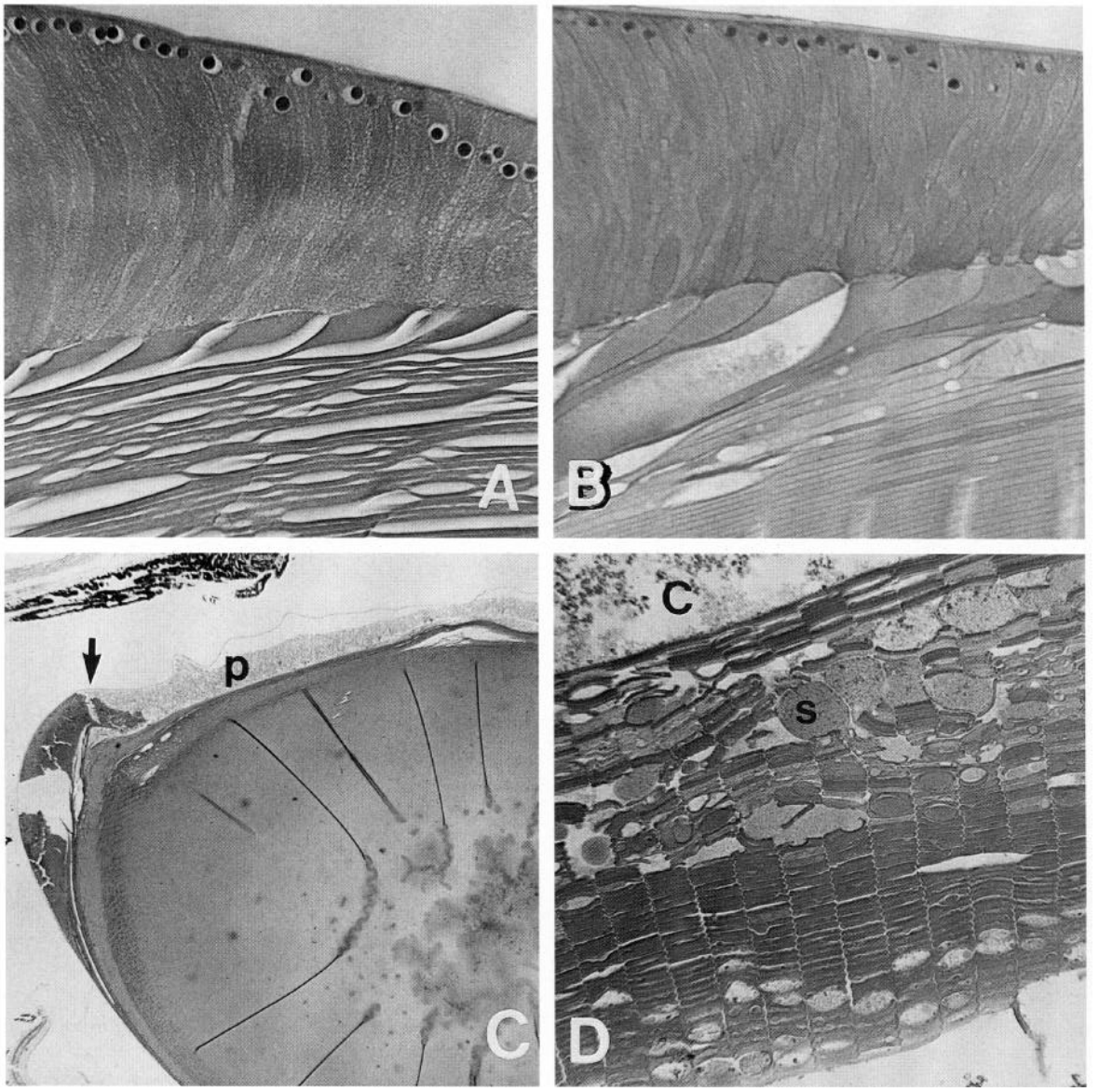

Figure 2. Ocular lenses from experimental mallards at Laguna Toston and William Sink. HE. **A.** Normal control mallard housed on dry land. **B.** Early lens fiber swelling in an experimental mallard housed on William Sink water. **C.** Disruption of the anterior lens pad (arrow) in an experimental mallard housed on Laguna Toston water, with release of granular protein material (p) into a thick liquified zone beneath the anterior capsule with lens fiber swelling and liquefaction of the equatorial and anterior cortex. **D.** Cortical lens fiber swelling and liquefaction (s). The outer cortex (c) is completely liquified in an experimental mallard housed on Laguna Toston water.

Mild granulocytic bronchitis and tracheitis was seen in approximately half of the wild waterfowl. Mild apoptosis was seen in the pancreas and moderate hemosiderin was seen in the spleen and liver. Bile stasis, sometimes with large bile plugs in bile ducts, was common.

An incomplete field survey, interrupted by Federal Government furloughs, was performed in October and November 1995. Evaluation of microscopic changes in 17 of the waterfowl found dead or moribund during the fall 1995 survey showed lesions similar to those seen in the spring 1995 survey. However, cloacal lesions were more frequent (7 of 13 birds) and severe and cholestasis was also more prominent in the waterfowl collected during the fall 1995.

Chemistry

Brains of all experimental mallards housed on playa water were in the toxic range. The average brain sodium concentration for experimental birds housed on Laguna Toston was 2,290 ppm, and average brain sodium concentration at Williams Sink was 2,831 ppm. The average brain sodium concentration for experimental mallards housed on land and provided Laguna

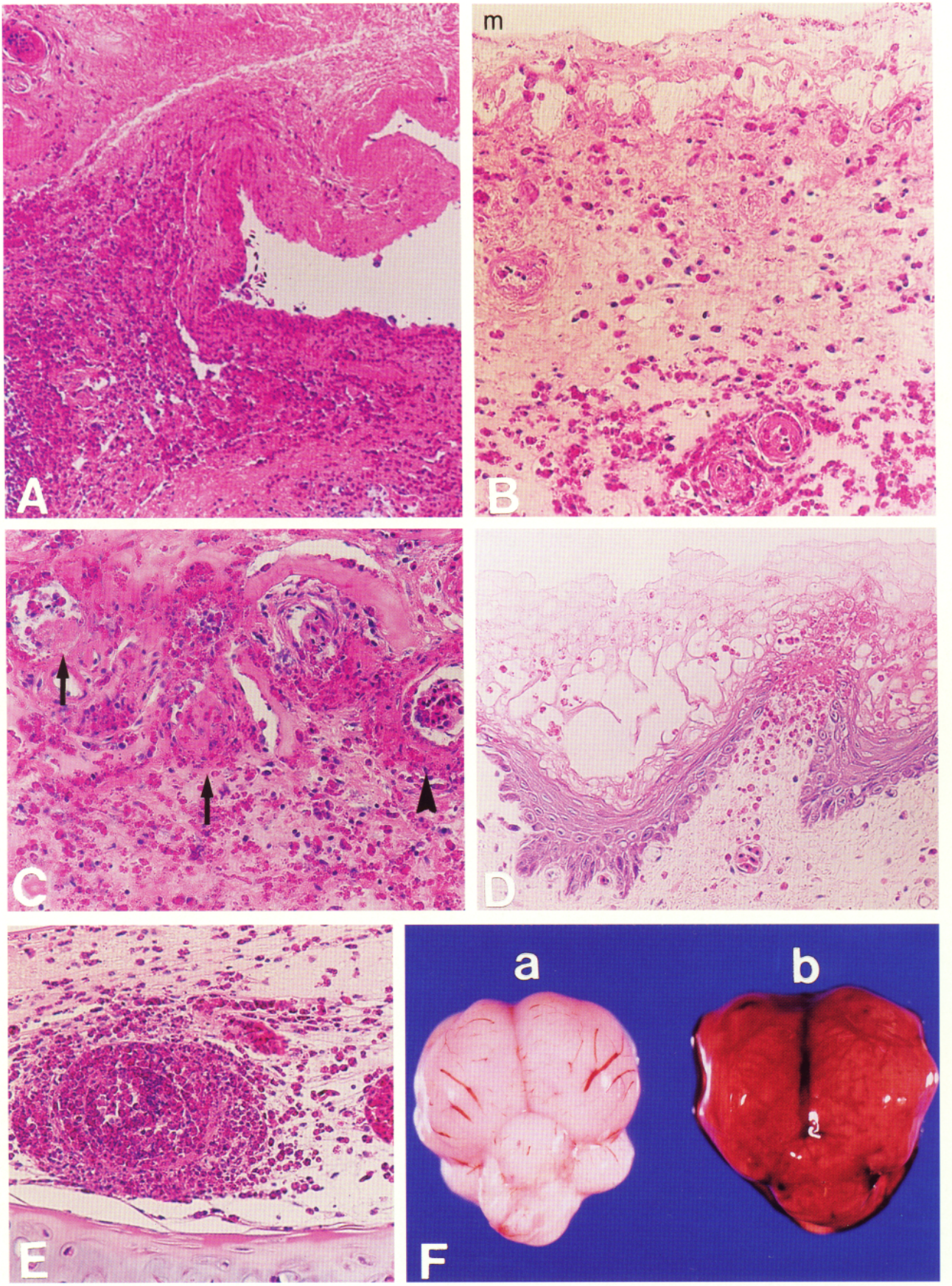
A
m
B
C
D
E
a
b
F

Toston water to drink was 1,690 ppm, and the average brain sodium concentration for mallards housed on land and provided Williams Sink water to drink was 1,661 ppm. The average brain sodium concentrations for the birds housed on land and provided fresh drinking water at Laguna Toston and Williams Sink were 1,305 and 1,413 ppm, respectively.

Brain sodium concentration was in the toxic range for 16 of 30 wild waterfowl collected from Laguna Toston, 1 of 3 birds from Laguna Dos, and the 1 bird from Laguna Tres. Two birds from Laguna Dos and the 1 bird from Laguna Quatro had brain sodium concentrations well beyond the physiological range (14,000-32,000 ppm), and the samples were considered contaminated with environmental sodium. Neither of 2 lesser scaup from Laguna Uno had brain sodium levels within the toxic range (average brain sodium concentration = 1,580 ppm); both scaup were alert and mobile when captured. The average brain sodium concentration for Laguna Toston birds that were euthanized was 2,070 ppm, whereas the average for the 10 birds found dead was 2,130 ppm.

The average percent error for duplicate sodium analyses was 5.4% and recovery of spike was 88%. Brain sodium concentration was not significantly different at 95% (paired t-test = 0.179) between samples of 7 normal turkey brains submitted in acid-washed jars (1383 ± 62.3 ppm) and samples submitted in sample bags (1391.3 ± 93.41 ppm).

Water collected November 1994 from Laguna Toston contained primarily sodium (19%), chloride (49%), and potassium (12%) with some sulfate (13%) and magnesium (7%); total dissolved solids was 310,000 ppm. Water composition from Williams Sink had relatively similar proportions of sodium (23%), chloride (54%), potassium (6%), sulfate (8%), and magnesium (4%), with total dissolved solids of 201,000 ppm. The pH of Laguna Toston was 7.4. Major constituents of salt collected from the feathers of mallards on Laguna Toston were chloride, sodium, and potassium; magnesium and sulfate were present in much lower concentrations.

Brain cholinesterase activity was within the normal range for all 28 birds tested. No lead was detected in the 9 livers analyzed.

Bacteriology

No significant bacteria were isolated from culture of 56 livers. No salmonellae were isolated from 10 intestine samples. Tests for avian botulism type C were negative for 30 birds

Virology/serology

No viruses were isolated from samples of 13 intestines and lungs.

Discussion

Coagulative necrosis, ulceration, and edema observed in the mucosa of conjunctiva, turbinate, hard palate, pharynx, and cloaca of playa lakes waterfowl indicate a rapid necrotizing event. Waterfowl on playa water often rubbed their heads on their wings and back with subsequent head shaking and frequent blinking, suggesting irritation possibly due to the hypersaline solution or salt crystals in the conjunctivae. Frequent preening of salt-laden feathers could have introduced the salt precipitate into the oral mucosa and pharynx and possibly cloaca if waterfowl were aggressive preening around the vent. The pathogenesis of the granulocytic inflammation and vasculitis with marked edema involving mucosal surfaces of the playa lakes waterfowl is not understood, but eosinophilic inflammation also characterizes the perivascular pathology in the brain of salt-poisoned swine. The role of eosinophils in salt poisoning of swine has also not been defined.[20]

Minimum single lethal dose of NaCl is reported to be 4 g of salt per kilogram of body weight for ≤ 9-week-old chickens.[1,25] Pekin ducks are more sensitive to sodium chloride poisoning than are other poultry.[31] If the experimental mallards are as sensitive to sodium chloride poisoning as are chickens or Pekin ducks and if the precipitated playa lakes crystals were pure sodium chloride, an approximate single dose of 4.3 g could be lethal for the average experimental mallard. With the frequent preening of heavily encrusted feathers on Laguna Toston experimental mallards, this quantity of salt could be ingested, and consumption of hypersaline playa water would only accentuate the so-

←

Figure 3. Lesions associated with salt poisoning in waterfowl. **A.** Necrosis and ulceration of conjunctiva, with heavy infiltration of granulocytes in the mucosa and submucosa; experimental mallard housed on Laguna Toston. **B.** Severe conjunctival edema with necrosis of mucosa (m); experimental mallard housed on Laguna Toston. **C.** Granulocytic vasculitis with hyalin degeneration of vessel walls (arrowhead) and thrombi (arrows) in the conjunctiva; experimental mallard housed on Laguna Toston water. **D.** Early lesion involving the pharyngeal surface of the glottis with ballooning of the epithelium, vesicle formation, and infiltration of the superficial epithelium with granulocytes; northern shoveler from Laguna Toston. **E.** Severe granulocytic vasculitis in the submucosa of the nasal turbinate; northern shoveler from Laguna Toston. **F.** Brains removed at necropsy: normal avian brain (a) and deeply congested brain from salt-poisoned, salt-encrusted lesser scaup from Laguna Toston (b).

dium load. Salt encrustation was more severe in wild birds picked up during the storm events occurring on April 11 and 17, 1995. Average salt precipitation on these dates was 68% and 60% of body weight, respectively (Table 1). Salt precipitate on carcasses collected on all other dates averaged 36% of body weight. Average lens pathology in dead birds associated with the April 17, 1995, storm was moderate to severe (grade 2.3, Table 1) and lens pathology for other ducks picked up during the 1995 spring survey was mild to moderate (grade 1.8, Table 1), suggesting that factors associated with storm events may influence cataract severity. There was no difference in average lens pathology between wild birds that were euthanized and those found dead (grade 1.8, Table 1). Severity of conjunctival lesions was not directly related to severity of lens changes, and conjunctival lesions were seen in only 11 of 37 wild waterfowl with cataracts (Table 1).

Cataracts are not commonly recognized in birds and are usually associated with trauma or senility.[19] All birds on playa water had some degree of lens pathology. The rapid onset and microscopic appearance of the cataracts suggest a rapid shift in the osmotic forces within the eye. Sodium poisoning was determined to be the cause of death or morbidity in 8 of the 8 experimental mallards on playa water and 18 of 37 wild waterfowl, and all birds with salt toxicosis had cataracts. However, brain sodium levels were not in the toxic range for 50% of the wild waterfowl with cataracts, suggesting that systemic hypernatremia was not the ultimate determining mechanism in the initiation of cataracts.

Cataract formation has not been mentioned in previous reports of sodium poisoning in birds[2,14,18,23,30,31,34,35] or mammals.[24] If playa lakes ducks introduce salt crystals into the conjunctiva by rubbing their eyes on salt encrusted feathers or if there is extensive direct contact of hypersaline playa water with the cornea, a shift in the osmolality of the anterior chamber fluid may cause subsequent disturbance of the osmolar homeostasis of the lens leading to lens fiber damage. Presmolt (not yet adapted to sea water) masu salmon developed cataracts within 1 hour of placement in sea water and osmolality of the aqueous humor in these salmon increased more rapidly than did plasma osmolality.[16] This rapid shift of aqueous humor osmolality suggested influx of electrolytes or loss of water directly through the cornea, contributing to the increased osmolality of the aqueous humor and subsequent cataract formation.[16] Increase in osmotic pressure in the aqueous humor due to evaporation of water through the cornea has also been proposed as the mechanism of cataract formation in mammals that could not close their eyelids.[4,11,32] Dehydration of the aqueous humor and lens was the most important factor in development of these cataracts.[12] The small volume of the anterior chamber of wild ducks make it more vulnerable to dehydration than the larger chamber of mammals. Cataracts have also been induced in extracted fish,[16] amphibian,[17] and mammalian lenses[32] exposed to hypertonic Ringer's solution and by intracameral injection of hypertonic so1ution.[21] The lenses of mammals and amphibians have been described as osmometers, which reflect the osmolarity of the aqueous humor.[6,9] These references give evidence for transcorneal movement of water with subsequent dehydration of the aqueous humor causing increased osmotic pressure on the lens. This mechanism for cataract formation seems applicable to playa lakes waterfowl that have a cornea exposed to hypersaline playa water and salt crystals and severely inflamed and edematous eyelids that may not be able to protect the cornea effectively. However, because the process can occur in extracted lenses, the osmolar process may have occurred postmortem in at least some of the birds, as is thought to have happened in a crissal thrasher found on the shore of Laguna Dos (Table 1); this passerine should not have had direct antemortem exposure to the playa water and had no measurable salt on the feathers. Necropsies were performed on all birds after overnight shipment, and lens pathology may have progressed as the birds became moribund or as a postmortem event if the cornea of the dead bird was exposed to salt or hypersaline solutions at the playa lakes or during shipment. The question of the biological significance of antemortem cataract formation could be answered by performing slit-lamp biomicroscopic examination of live ducks at the playa lakes. Osmotic cataracts can be reversible in some cases,[12] and the question of reversibility of cataracts in the playa lakes birds would also be biologically important to answer.

Vacuolation of renal tubule epithelium has been reported in cases of salt poisoning in turkey poults.[14] This lesion was seen in 11/18 wild waterfowl with brain sodium concentration in the toxic range.

The differences in degree and rate of salt encrustation, severity of clinical signs, and survivability of experimental mallards housed on Laguna Toston versus Williams Sink may be due to differences in weather, local topography, degree of salinity of playa water, and/or bird behavior at the individual playas. Field observations during spring 1994 also suggested that Williams Sink may not be as inhospitable to migrating waterfowl as Laguna Toston; no mortality was observed at Williams Sink during migratory bird surveys. Salt poisoning was the primary cause of death in both experimental and wild waterfowl at all of the playa lakes surveyed. Mucosal lesions are thought to be due to contact irritation from hypersaline water or salt crystals and duration of exposure and weather may influ-

ence severity of lesions. Clinical signs and pathology indicate mucosal irritation from playa water and, if the cataracts are shown to be antemortem, the ocular irritation and poor vision secondary to the cataracts may prevent the waterfowl from leaving the playa thus making them vulnerable to salt poisoning.

Acknowledgements

We acknowledge the advice and manuscript review provided by Drs. Anita Kore and Paul Miller, with technical assistance provided by Dr. Milton Smith, Terry Creekmore, Dan Finley, Lisa M. Wochinski, IMC Global, Inc., and Phillip Herold. Clerical assistance was provided by Cathy Acker. Field support during the experimental trial was provided by Diana Goldberg. Field support for the spring 1995 survey in New Mexico was conducted by Scott Yaeger, Brent C. Bauer, and Sheila Mahoney and directed by Joseph R. Jehl. Clint Jeske and the Southern Science Center supervised field work for the fall 1995 survey. Assistance from the US Bureau of Land Management, US Fish and Wildlife Service, and New Mexico Cooperative Fish and Wildlife Research Unit is also appreciated. Partial funding for this project was provided by the US Bureau of Land Management.

Sources and manufacturers

a. Wild Wings, Oneka, MN.
b. Nitrile N-DEX gloves. Best Manufacturing Co., Menlo, GA.
c. Fisher Scientific, Pittsburgh, PA.
d. Surgipath Medical Industries, Richmond, IL.
e. Corning Science Products, Corning Glass Works, Coming, NY.
f. Difco Laboratories, Detroit, MI.
g. Biomerieux Vitek, Hazelwood, MO.

References

1. Austic RE, Scott ML: 1991, Nutritional diseases. *In:* Diseases of poultry, ed. Calneck BW, Barnes HJ, Beard CW, et al., 9th ed., p. 63. Iowa State University Press, Ames, IA.
2. Bennett DC, Bowes VA, Hughes MR, Hart LE: 1992, Suspected sodium toxicity in hand-reared great blue heron (*Ardea herodias*) chicks. Avian Dis 361743-748.
3. Bureau of Land Management: 1976, Executive summary and supplement to preliminary potash environmental analysis record, pp. 4, 11. Bureau of Land Management, New Mexico State Office, Santa Fe, NM.
4. Calderone L, Grimes P, Shalev M: 1986, Acute reversible cataract induced by xylazine and by ketamine-xylazine anesthesia in rats and mice. Exp Eye Res 42:331-337.
5. Chico RL: 1968, Playa. *In:* The encyclopedia of geomorphology, ed. Fairbridge RW, pp. 865-871. Reinhold Book Corp., New York, NY.
6. Cotlier E, Kwan B, Beaty C: 1968, The lens as an osmometer and the effects of medium osmolarity on water transport, ^{86}Rb efflux and ^{86}Rb transport by the lens. Biochem Biophys Acta 150:705-722.
7. Davis DR, Hopkins JS: 1993, Lake water quality assessment surveys 1992. Surveillance and Standards Section, Surface Quality Bureau, New Mexico Environmental Department, Santa Fe, NM.
8. Docherty DE, Slota PG: 1988, Use of muscovy duck embryo fibroblasts for the isolation of viruses from wild birds. J Tissue Cult Methods 11:165-170.
9. Duncan G: 1970, Permeability of amphibian lens membranes to water. Exp Eye Res 9:188-197.
10. Ellman GL, Courtney KK, Andrew V Jr, Featherstone R: 1961, A new and rapid calorimetric determination of acetylcholinesterase activity. Biochem Pharmacol 7:88-95.
11. Fraunfelder FT, Burns RP: 1960, Effect of lid closure in drug-induced experimental cataracts. Arch Ophthalmol 76:599-601.
12. Fraunfelder FT, Burns RP: 1970, Acute reversible lens opacity: caused by drugs, cold, anoxia, asphyxia, stress, death and dehydration. Exp Eye Res 10: 19-30.
13. Geohydrology Associates: 1979, Water-resources study of the Carlsbad potash area, New Mexico, pp. 20, 60-61. Geohydrology Assoc., Albuquerque, NM.
14. Gitter M, Lewis G, Crossman PJ, Don PL: 1979, Salt poisoning in turkey poults. Br Vet J 135:55-63.
15. Hill EF, Fleming WJ: 1982, Anticholinesterase poisoning of birds: field monitoring and diagnosis of acute poisoning. Environ Toxicol Chem 1:27-38.
16. Iwata M, Komatsu S, Collie NL, et al.: 1987, Ocular cataract and seawater adaptation in salmonids. Aquaculture 66:315-327.
17. Jacob TJC, Duncan G: 1980, Osmotic influences of lens membrane characteristics. Exp Eye Res 31:505-512.
18. Julian RJ: 1991, Poisons and toxins. *In:* Diseases of poultry, ed. Calneck BW, Barnes HJ, Beard CW, et al., 9th ed., pp. 866-867. Iowa State University Press, Ames, IA.
19. Keymer IF: 1977, Cataracts in birds. Avian Pathol 6:335-341.
20. Koestner A, Norton S: 1991, Nervous system. *In:* Handbook of toxicologic pathology, ed. Haschek WM, Rousseaux CG, pp. 663-664. Academic Press, San Diego, CA.
21. Lazar M, Rosen N, Nemet P: 1977, Miochol-induced transient cataract. Ann Ophthalmol 9:1142-1143.
22. Locke LN, Smith MR, Windingstad RM, Martin SJ: 1991, Lead poisoning of a marbled godwit. Prairie Nat 23:21-24.
23. Mohanty GC, West JL: 1969, Pathologic features of experimental sodium chloride poisoning in chicks. Avian Dis 13:762-773.
24. Osweiler GD, Carson TL, Buck WB, Van G-elder GA: 1985, Water deprivation-sodium salt. *In:* Clinical and diagnostic veterinary toxicology, 3rd ed., pp. 167-170. Kendall/Hunt, Dubuque, IA.
25. Quigley GD, Waite RH: 1932, Salt tolerance of baby chicks. Md Agric Exp Stn Bull 340:343.
26. Quortrup ER, Sudheimer RL: 1943, Detection of botulism toxin in the blood stream of wild ducks. J Am Vet Med Assoc 102: 264-266.
27. Rand MC, Greenberg AE, Taras MJ, eds.: 1975, Determination of metals, and determination of inorganic nonmetallic constituents. *In:* Standard methods for the examination of water and wastewater, 14th ed., pp. 143-500. American Public Health Assoc., American Water Works Assoc., and Water Pollution Control Federation, Washington, D.C.
28. Reed AJ: 1985, Evaluation of Southern Nash Draw for potential disposal of brine water, Eddy County, New Mexico, pp. 4-5. Ed L. Reed and Associates, Corpus Christi, TX.
29. Senne DA: 1989, Virus propagation in embryonated eggs. *In:* A laboratory manual for the isolation and identification of avian pathogens, ed. Purchase HG, Arp LH, Domermuth CH, Pearson JE, 3rd ed., pp. 176-181. American Association of Avian Pathologists, Kennet Square, PA.
30. Swayne DE, Shlosberg A, Davis RB: 1986, Salt poisoning in turkey poults. Avian Dis 30:847-852.
31. Torrey JP, Graham R: 1935, A note on experimental salt poisoning in ducks. Cornell Vet 25:50-53.

32. Weinstock M, Scott JC: 1967, Effect of various agents on drug-induced opacities of the lens. Exp Eye Res 6:368-375.
33. Westerman RL, ed.: 1990, Soil testing and plant analysis, 3rd ed., pp. 410-420. Soil Science Society of America, Madison, WI.
34. Windingstad RM, Kartach FX, Stroud RK, Smith MR: 1987, Salt toxicosis in waterfowl in North Dakota. J Wildl Dis 23: 443-446.
35. Wobeser G, Howard J: 1987, Mortality of waterfowl on a hypersaline wetland as a result of salt encrustation. J Wildl Dis 23:127-134.