

Sarcocystis

Synonyms

Rice breast disease, sarcosporidiosis, sarcocystosis

Cause

Sarcocystis is a nonfatal, usually asymptomatic infection that is caused by a parasitic protozoan. Various species of this parasite affect mammals, reptiles, and birds. The most commonly reported species of the parasite in North America is *Sarcocystis rileyi*, the species most commonly found in waterfowl.

Life Cycle

The *Sarcocystis* sp. parasites have an indirect life cycle (Fig. 28.1) that requires a paratenic or transport host animal (a bird), in which they live for a time before they are trans-

ported to a definitive host animal (a carnivore), in which they reach maturity. Birds ingest the eggs or oocysts of the mature parasite in food or water that is contaminated by carnivore feces, which contain the oocysts. The oocysts develop in the intestine of the bird into an intermediate form, the sporozoites, that enter the bird's bloodstream and infect specific cells of the blood vessels. Multiplication of these cells gives rise to a second intermediate form, merozoites, that are carried by the blood to the voluntary muscles, where elongated cysts or macrocysts are eventually produced (Fig. 28.2). The life cycle is completed when a carnivore ingests the infected muscle tissue of a bird and the parasite reaches maturity and releases oocysts in the intestines of the carnivore. The carnivore is infected only in its intestine. Macrocysts do

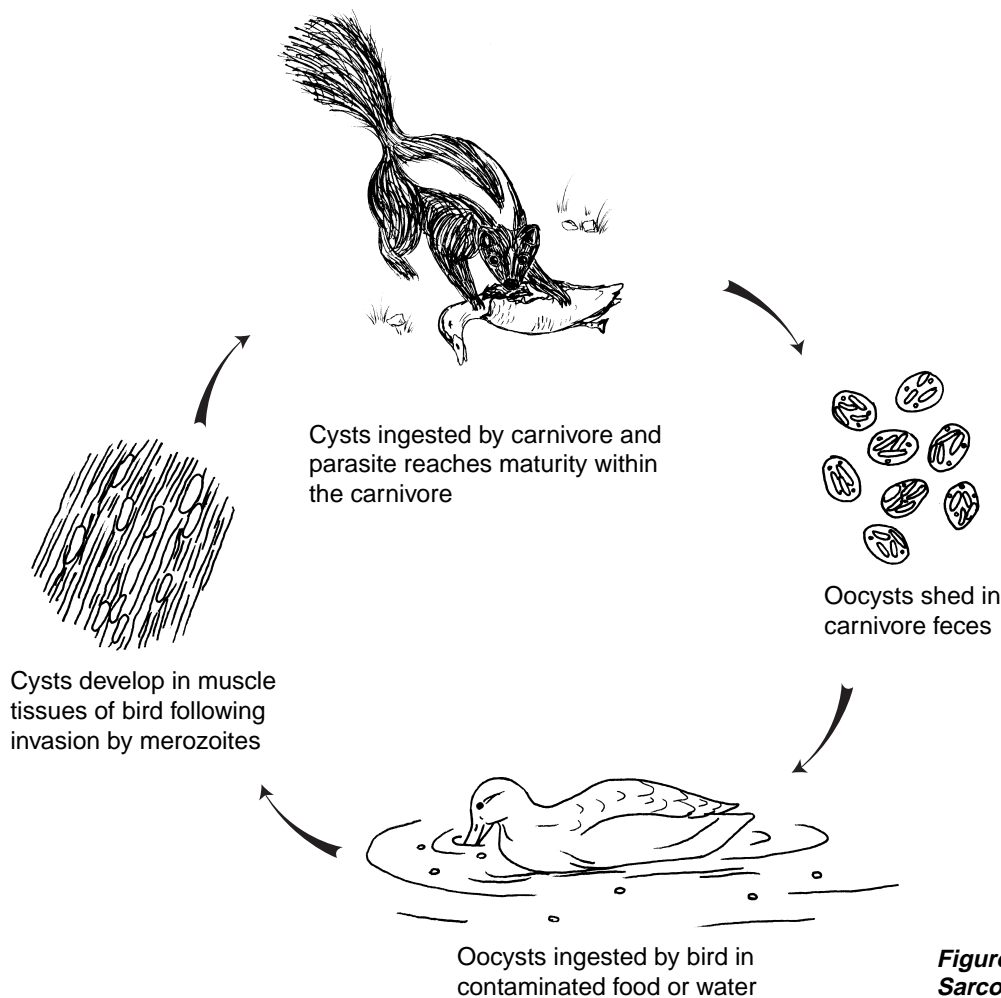
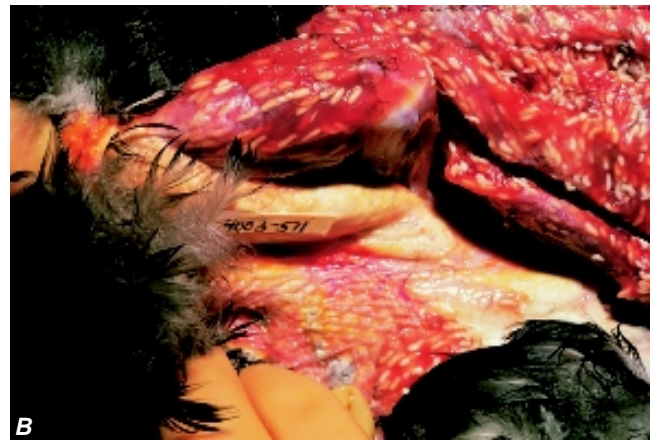
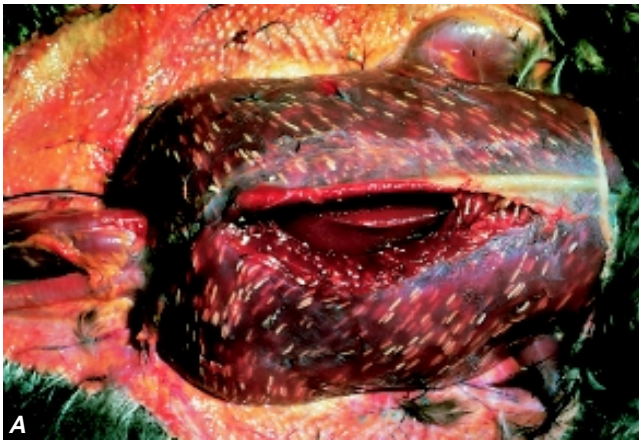
Figure 28.1 General life cycle of *Sarcocystis* sp.



Photos by James Rumminger

Figure 28.2 Rice-grain sized cysts of *Sarcocystis* sp. evident in parallel streaks in **A**, breast muscle fibers of a mallard and **B**, thigh and leg muscle of an American black duck.

not develop in the carnivore, and the *Sarcocystis* sp. parasite rarely causes the carnivore illness or other forms of disease.

Species Affected

Dabbling ducks (mallard, northern pintail, northern shoveler, teal, American black duck, gadwall, and American wigeon) commonly have visible or macroscopic forms of *Sarcocystis* sp.; these forms are far less frequently found in other species of ducks and are infrequently found in geese and swans. Recent studies of wading birds in Florida have disclosed a high prevalence of *Sarcocystis* sp.; similar findings have previously been reported from South Africa. Land birds, such as grackles and other passerine birds, as well as mammals and reptiles can have visible forms of sarcocystis, but it is unlikely that *S. rileyi* is the species of parasite involved. With the exception of waterfowl, this parasite has received little study in migratory birds. This must be taken into account when considering the current knowledge of species affected (Fig. 28.3).

Distribution

Sarcocystis is a common parasitic infection of some waterfowl species, and it is found throughout the geographic range of those species in North America. Less is known about *Sarcocystis* sp. in other species of wild birds, but this parasite has been reported from waterbirds in South Africa, Australia, Canada, and Mexico in addition to the United States.

Seasonality

Infected birds can be found yearround, but waterfowl that are infected with *Sarcocystis* sp. are usually observed during the hunting season. Infection is not seen in prefledgling waterfowl, nor is it often seen in juveniles. Two possible reasons for these differences between the age classes may be

that the development of visible forms of the parasite requires time or that birds may not be infected until after they have left their breeding grounds. Because visible forms of sarcocystis are more frequently developed in older birds, hunter detection tends to be greatest during years of poor waterfowl production when the bag contains a greater proportion of adult birds. A moderate percentage of juvenile mottled ducks that were collected in Louisiana primarily after the hunting season were recently found to have light sarcocystis infections. Because this species does not migrate, this suggests that the birds were infected within the general geographic area where they were collected and that the later collection date allowed the macrocyst lesions to be visible.

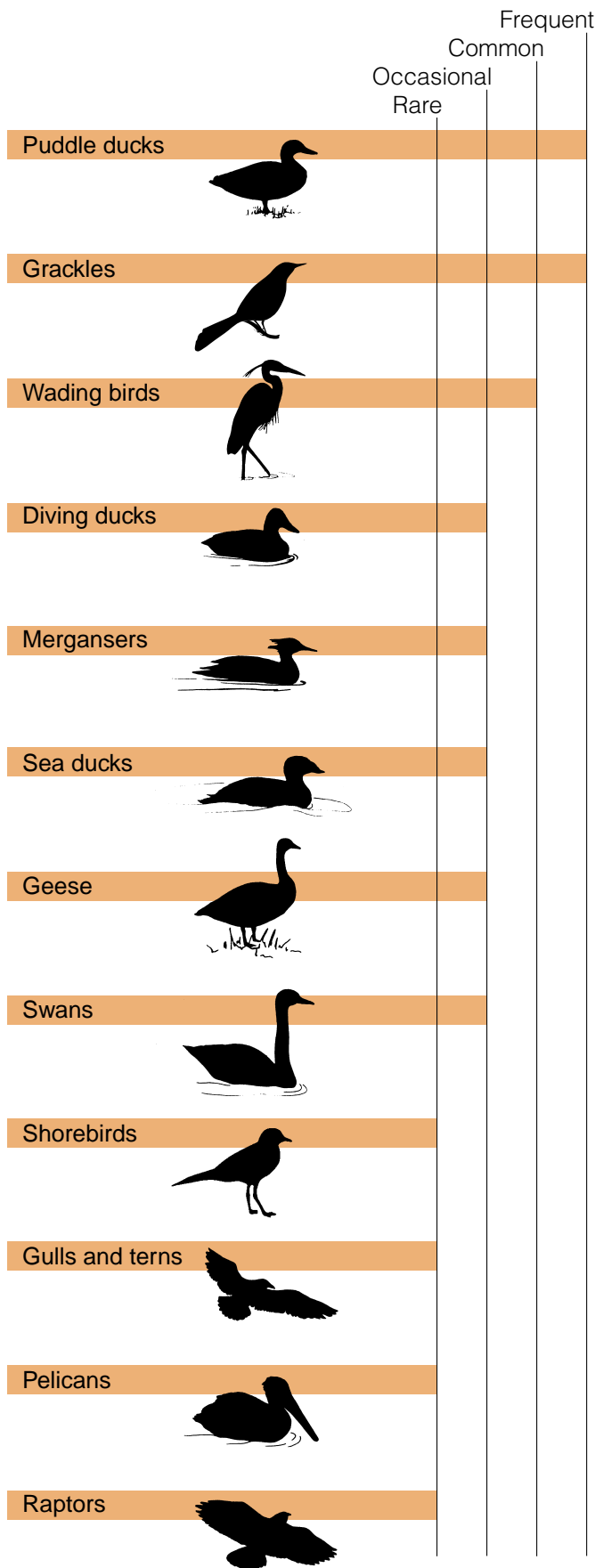
Too little is known about sarcocystis in other groups of wild birds to evaluate its seasonality.

Field Signs

Usually, there is no externally visible sign of this disease nor is it recognized as a direct cause of migratory bird mortality. Severe infections can cause loss of muscle tissue and result in lameness, weakness, and even paralysis in rare cases. The debilitating effects of severe infections could increase bird susceptibility to predation and to other causes of mortality.

Gross Lesions

Visible forms of infection are readily apparent when the skin is removed from the bird. In waterfowl and in many other species, infection appears as cream-colored, cylindrical cysts (the macrocysts) that resemble grains of rice running in parallel streaks through the muscle tissue. The cysts are commonly found in the breast muscle (Fig. 28.2A), but they are also found in other skeletal and cardiac muscle (Fig. 28.2B). Calcification of the muscle tissue around these cysts



makes them obviously discrete bodies. The degree of calcification is often sufficient to give a gritty feeling to the tissue when it is cut with a knife.

Lesions that were observed in wading birds differed in appearance; the cysts were white and opaque, and they generally extended throughout the entire length of the infected muscle fiber. Cysts were present in the heart muscle and they were confined to striated muscles.

Diagnosis

The visible presence of sarcosporidian cysts in muscle tissue is sufficient to diagnose this disease. Visible cysts may vary in size and shape in different bird species. Good quality color photographs (prints or 35 millimeter slides) of the external surface of infected muscle are generally sufficient for a disease specialist to recognize this disease if tissues or a whole carcass cannot be provided. Whole birds should be submitted if possible. If only tissues can be submitted, then a portion of the infected muscle should be fixed in a 10 percent formalin solution. Frozen muscle tissue is also suitable for diagnosis, and the distinctive appearance of these cysts allows a diagnosis from even partially decomposed carcasses.

Control

There are no known control methods for this disease, nor do any seem to be needed or are any being developed. Control of sarcocystis would require interruption of the life cycle of the parasite. Although the life cycles of the *Sarcocystis* sp. that affect wild birds are not precisely known, they are probably similar to the two-host, indirect life cycle known for some other *Sarcocystis* sp. (Fig. 28.1). The predator-prey relationship between the intermediate bird hosts and the definitive carnivore hosts may be the primary reason that juvenile birds or some bird species are seldom found to be infected. The appropriate carnivores may not be present on the breeding grounds.

Different species of carnivores seem to be involved in the infection of different bird species, which suggests that birds are infected by more than one species of the genus *Sarcocystis* sp. If the carnivore-bird cycle is species-specific, that is, if a specific species of bird can only be infected by oocysts that are produced by a parasite in a specific carnivore species, then selective control of sarcocystis might be feasible. However, current knowledge of the disease does not indicate a need to initiate control because there is little evidence that bird health is often compromised by infection. Nevertheless, the role of carnivores in the life cycle of *Sarcocystis* sp. infections should be considered when feeding

Figure 28.3 Relative frequency of grossly visible forms of *sarcocystis* in selected groups of North American migratory birds.

uncooked, infected waterfowl to house pets and to farm animals such as hogs.

Human Health Considerations

Sarcocystis sp. presents no known health hazard to humans. The primary importance to humans of sarcocystis in waterfowl is the loss of infected birds for food; the unaesthetic appearance of parasitized muscle may prompt hunters to discard the carcass. Limited evaluations of hunter responses to infected carcasses indicate no reduction in carcass consumption in areas where the infection is commonly seen. Also, the recognized high prevalence of infection in northern shovelers in some areas results in this species often being left unretrieved by some hunters and focuses additional hunting pressure on other species.

Benjamin N. Tuggle and Milton Friend

(Modified from and earlier chapter by Benjamin N. Tuggle)

Supplementary Reading

- Cawthorn, R.J., Rainnie, D., and Wobeser, G.A., 1981, Experimental transmission of *Sarcocystis* sp. (Protozoa: Sarcocystidae) between the shoveler (*Anas clypeata*) duck and the striped skunk (*Mephitis mephitis*): *Journal of Wildlife Diseases*, v. 17, p. 389–394.
- Cornwell, G., 1963, New waterfowl host records for *Sarcocystis rileyi* and a review of sarcosporidiosis in birds: *Avian Disease*, v. 7, p. 212–216.
- Moorman, T.E., Baldassarre, G.A., and Richard, D.M., 1991, The frequency of *Sarcocystis* spp. and its effect on winter carcass composition of mottled ducks: *Journal of Wildlife Disease*, v. 27, no. 3, p. 491–493.
- Spalding, M.G., Atkinson, C.T., and Carleton, R.E., 1994, *Sarcocystis* sp. in wading birds (Ciconiiformes) from Florida: *Journal of Wildlife Disease*, v. 30, no. 1, p. 29–35.